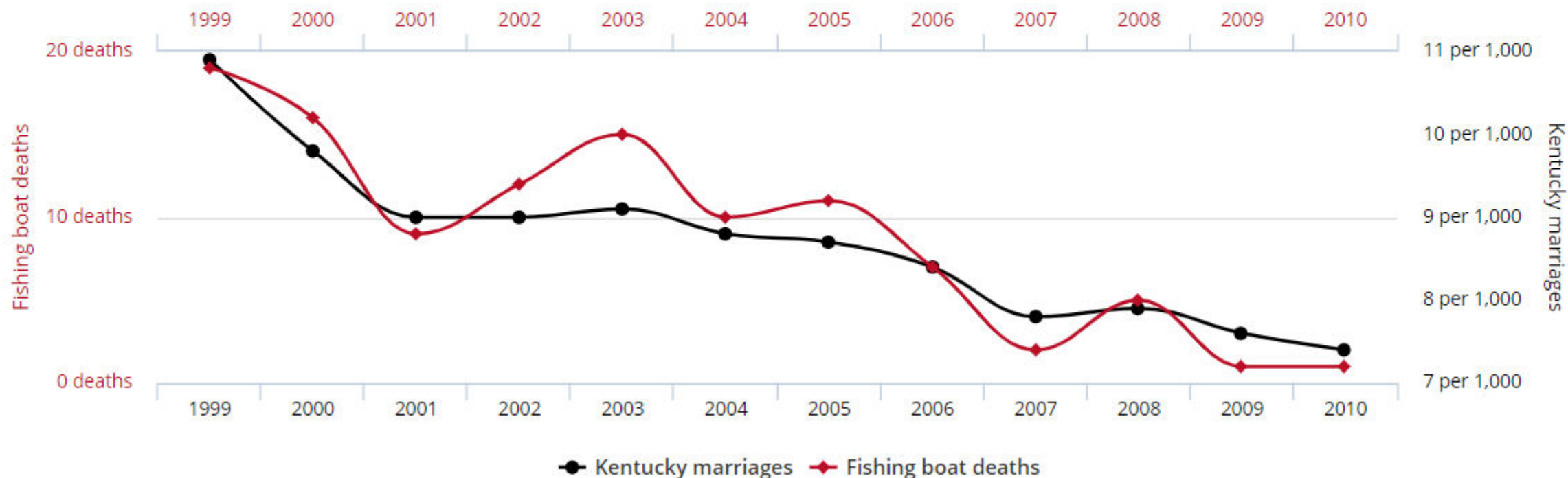


People who drowned after falling out of a fishing boat correlates with Marriage rate in Kentucky

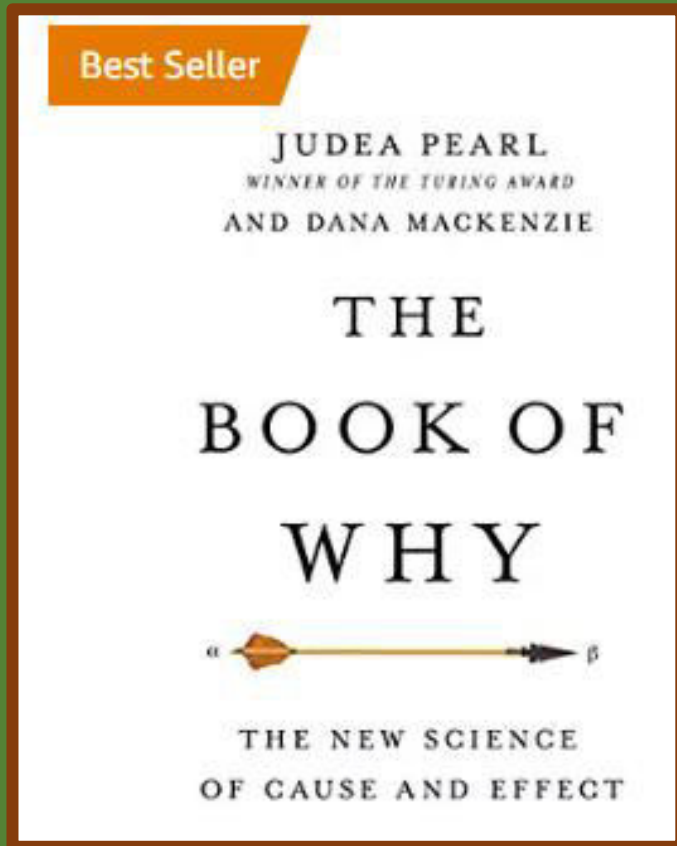
Correlation: 95.24% ($r=0.952407$)



Data sources: Centers for Disease Control & Prevention and National Vital Statistics Reports

tylervigen.com

Correlation is not causation



A Turing Award-winning computer scientist and statistician shows how understanding causality has revolutionized science and will revolutionize artificial intelligence.

The Harper Fragment

David W. Mantik

JFK Assassination Conference

November 17-18, 2018

Mantik
e-book:
on
Amazon

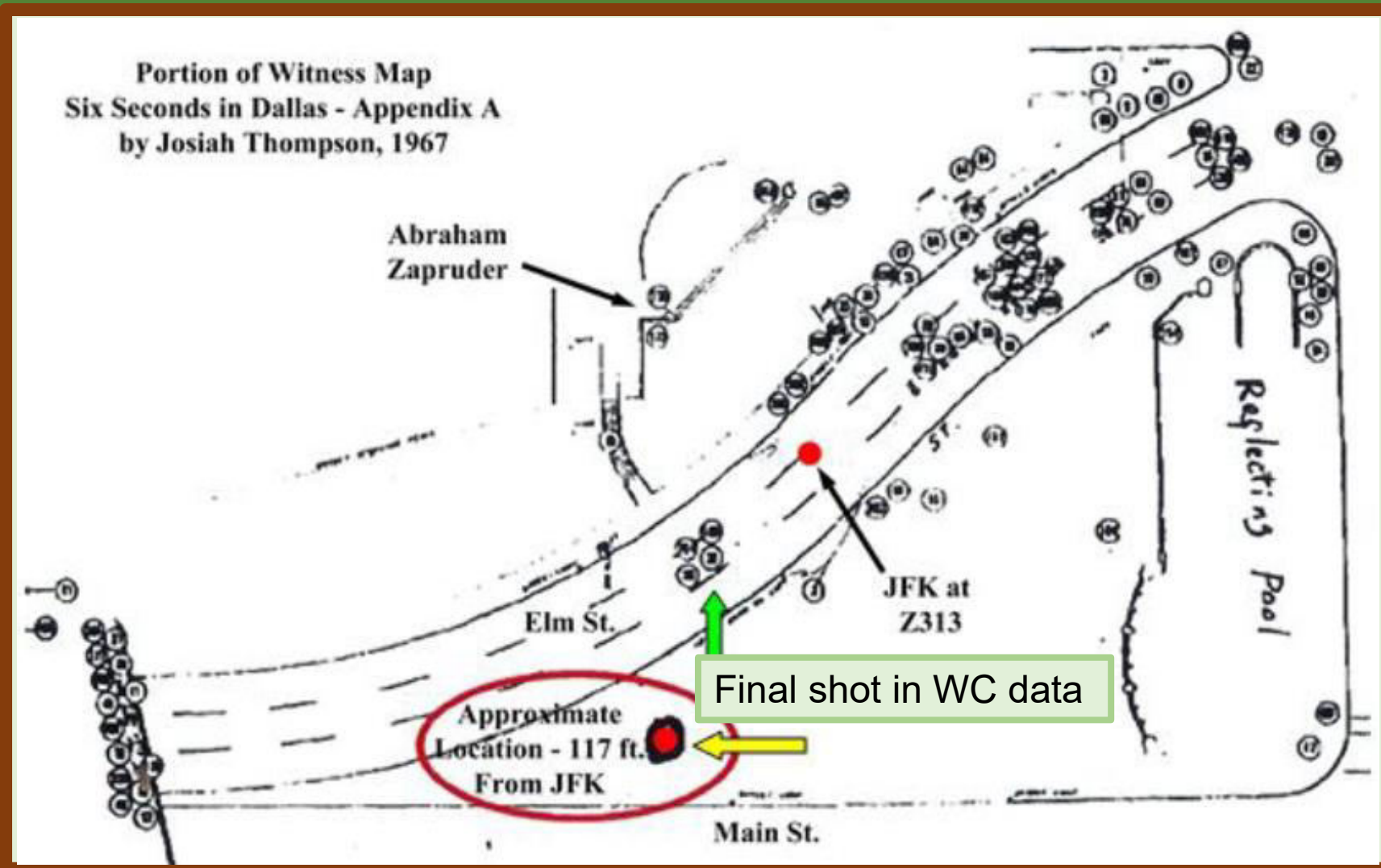
JFK'S HEAD WOUNDS

A Final Synthesis — and a New Analysis of
the Harper Fragment



David W. Mantik, M.D., Ph.D.

Billy Harper marked this map



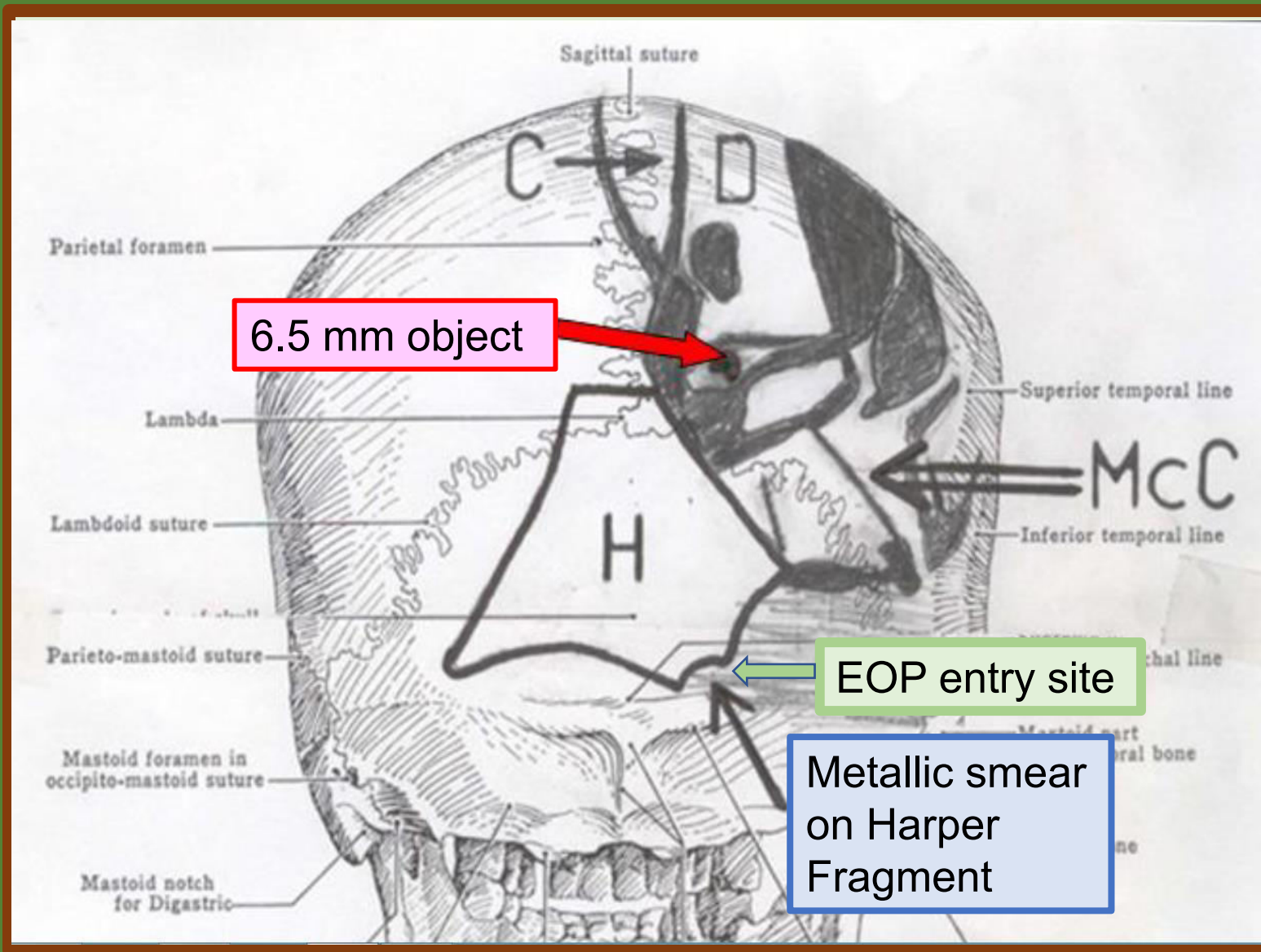
The Harper Fragment: Why is it important?

- If HF derives from the occiput, then a frontal shot is strongly implied
- And that means conspiracy

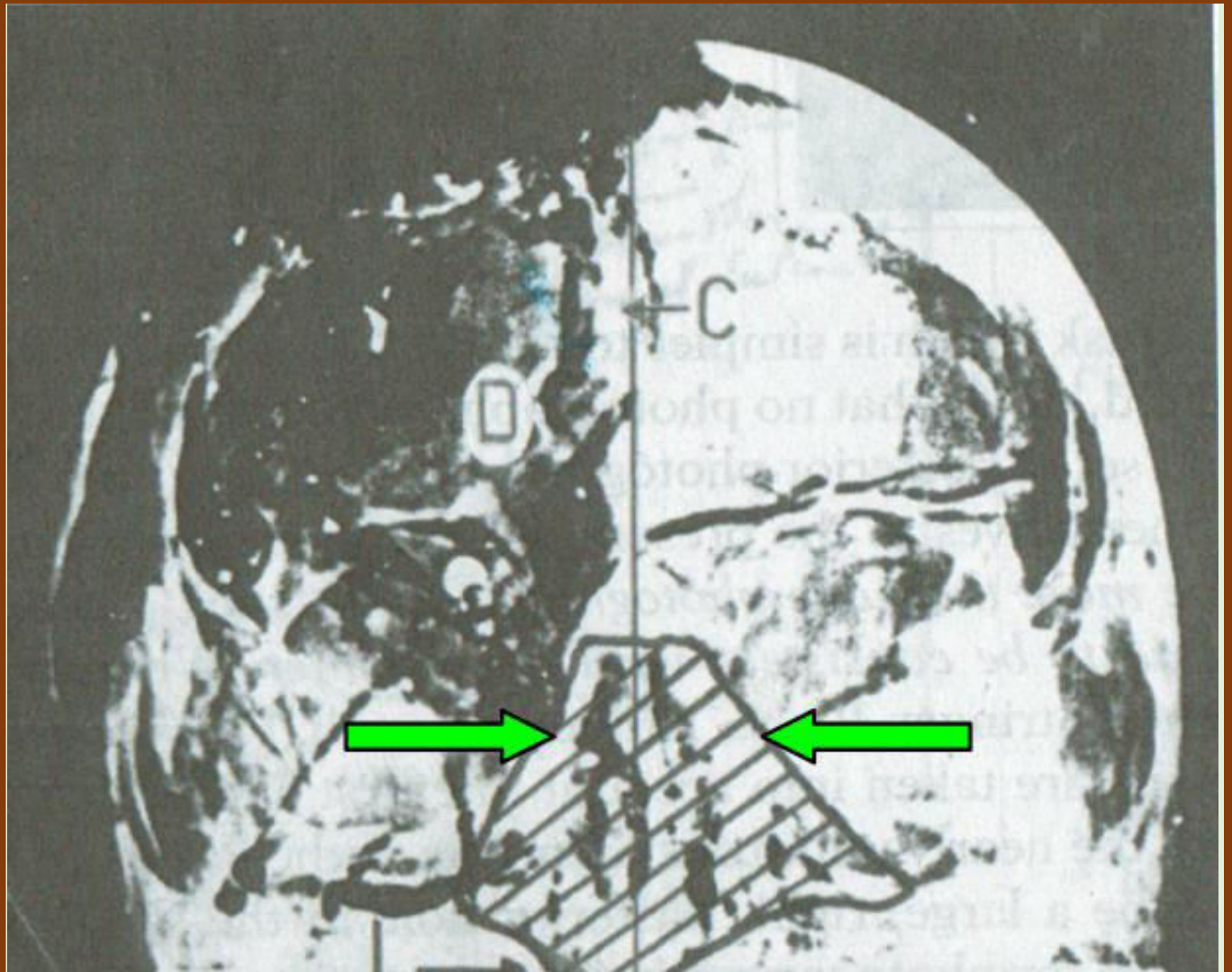
HF: It's parietal (or so they claim)!

- Randy Robertson, MD
- Joe Riley, PhD
- J. Lawrence Angel, PhD
- Richard Tobias
- Pat Speer
- HSCA

Harper (H)
Site of
Origin—as
viewed from
the
posterior
(per Mantik)



HF Site of
Origin—on
AP X-ray
(per Mantik).



No lambdoid sutures superior to tip of green
arrows → bone is missing there bilaterally

Actual sentences found in patients' hospital charts

Her lab test indicated abnormal liver
function.

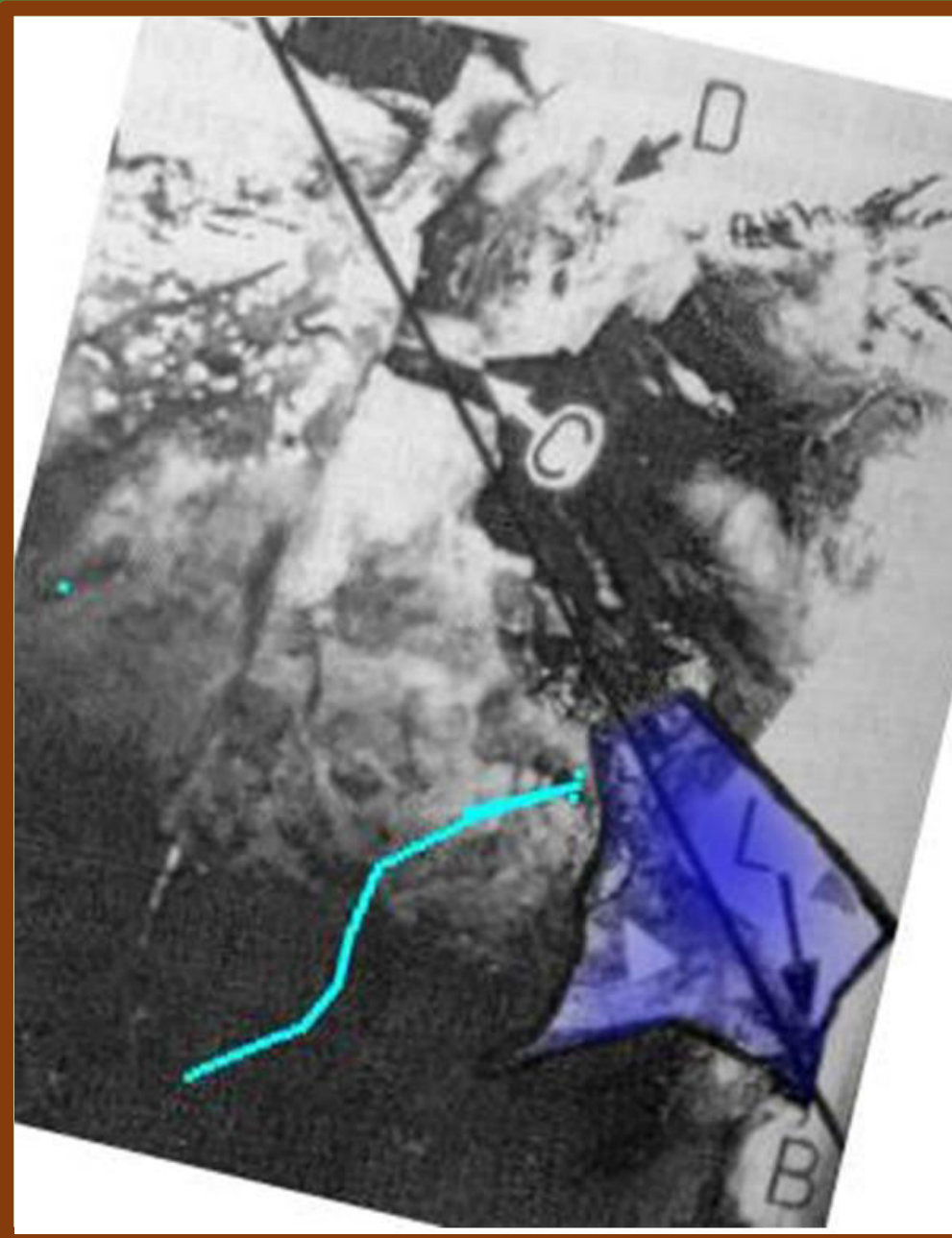
Serendipity Strikes

- I located HF in the skull, based purely on where it fit—after an extensive radiographic reconstruction in our radiology suite, by precisely matching the bone fragments from the JFK X-rays to my model skull. No one else has done this.
- It was pure serendipity that the metallic debris on HF ended up exactly where Humes placed the entry near the EOP. What are these odds?


HF Site of Origin—on the mystery photo F8 (per Mantik)

The black line divides
the left skull from the
right skull


F8 = official autopsy
nos. 17, 18, 44, 45



HF--as photographed in Dallas



HF--as photographed by the FBI

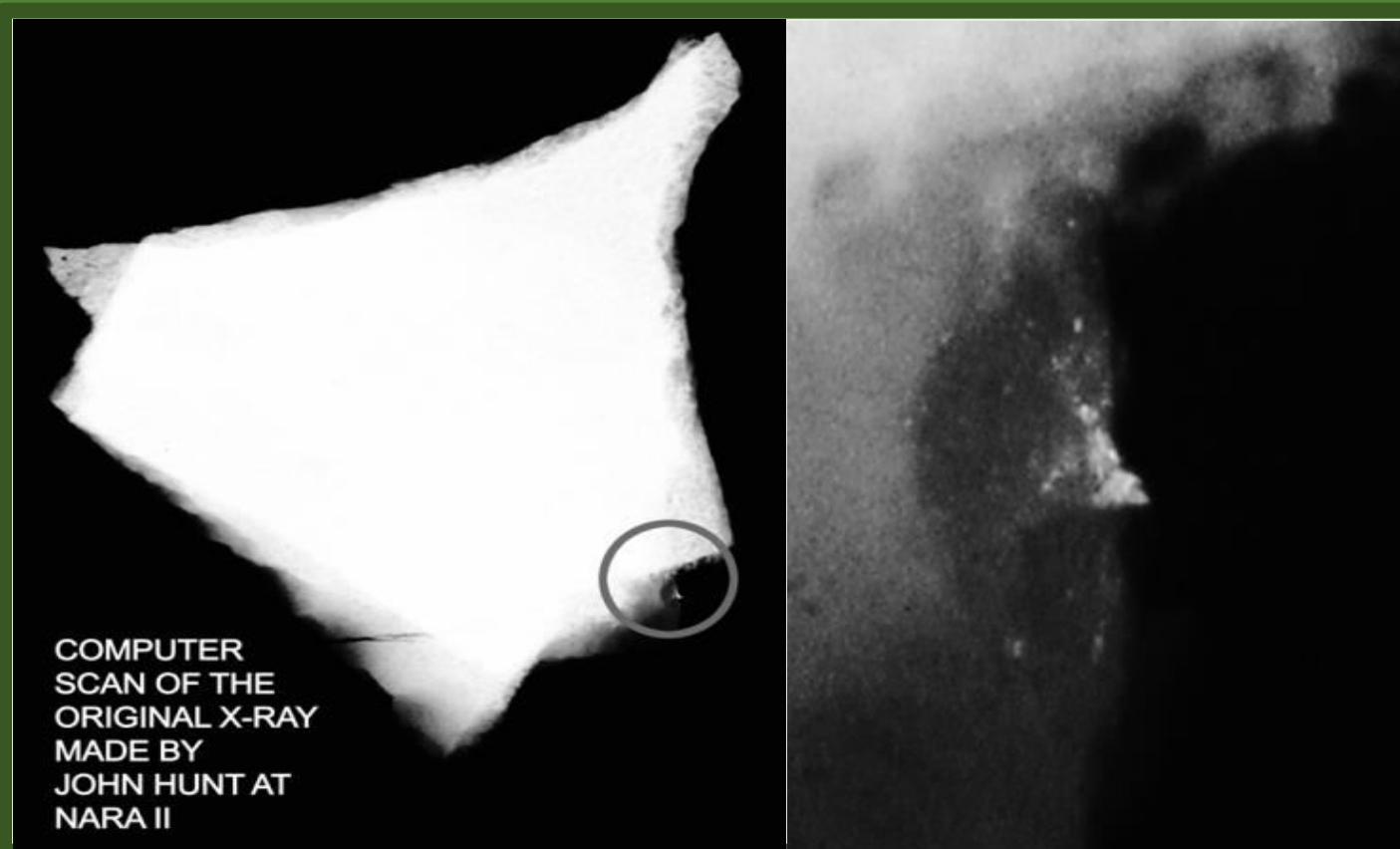


HF Photo vs. X-ray: the metallic debris matches!



HF X-ray:

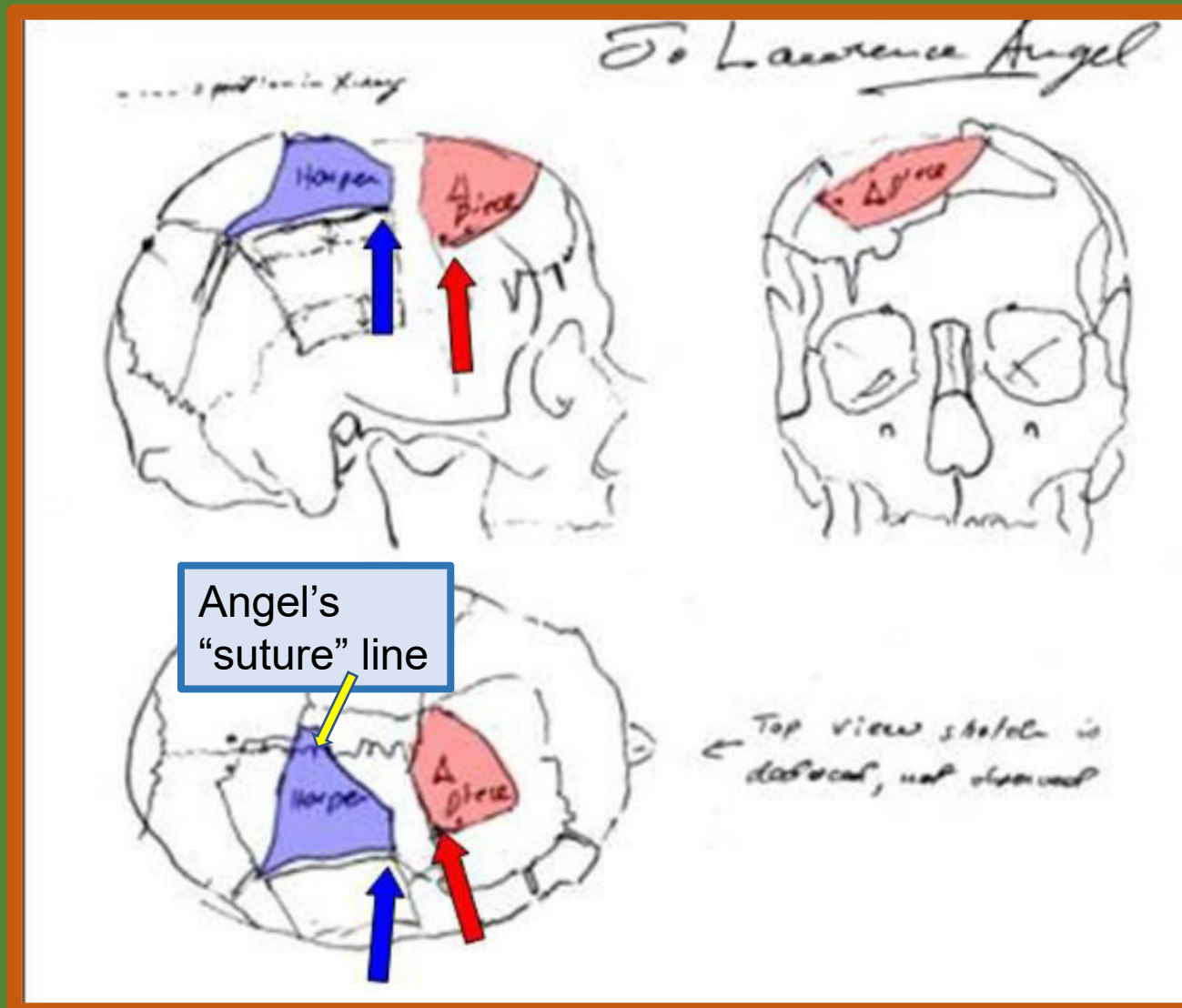
1. Notice debris on magnified view (red circle)
2. No suture line! (Dr. Angel was misled.)




Actual sentences found in patients' hospital charts

She has no rigors or shaking chills, but her husband states she was very hot in bed last night.

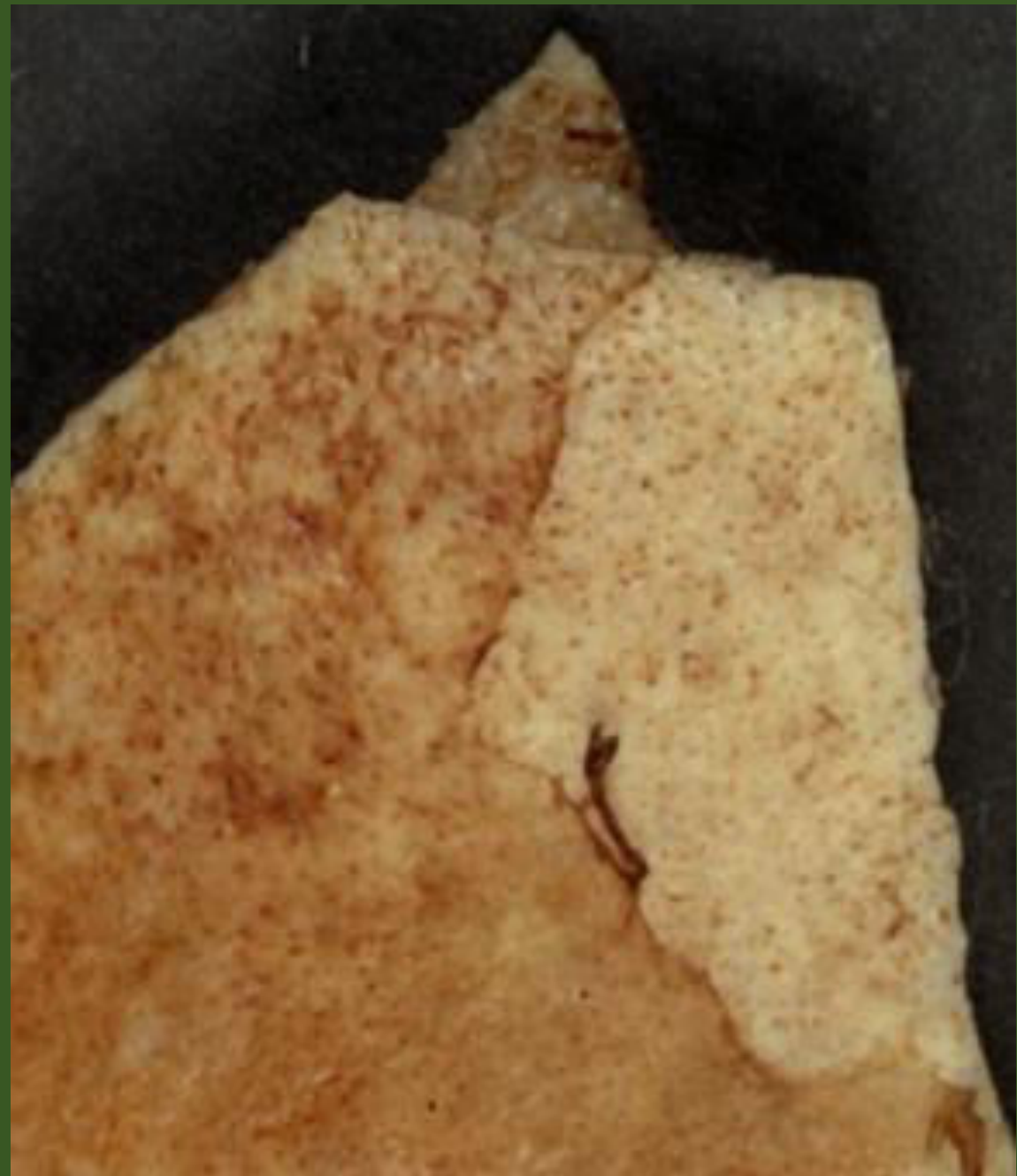HF: as (mis)located by Angel.
There was no suture!



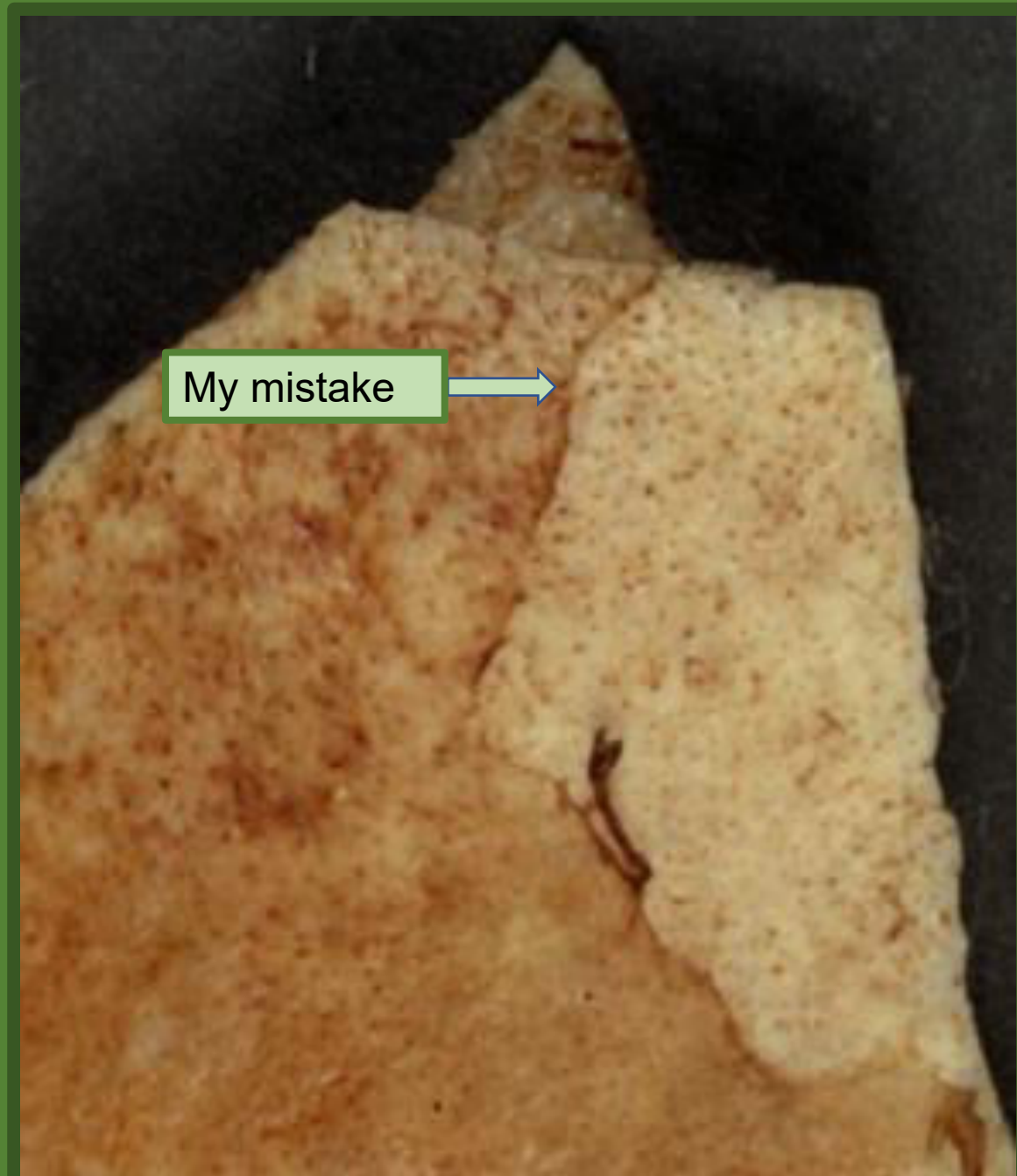HF: Angel's "suture" line



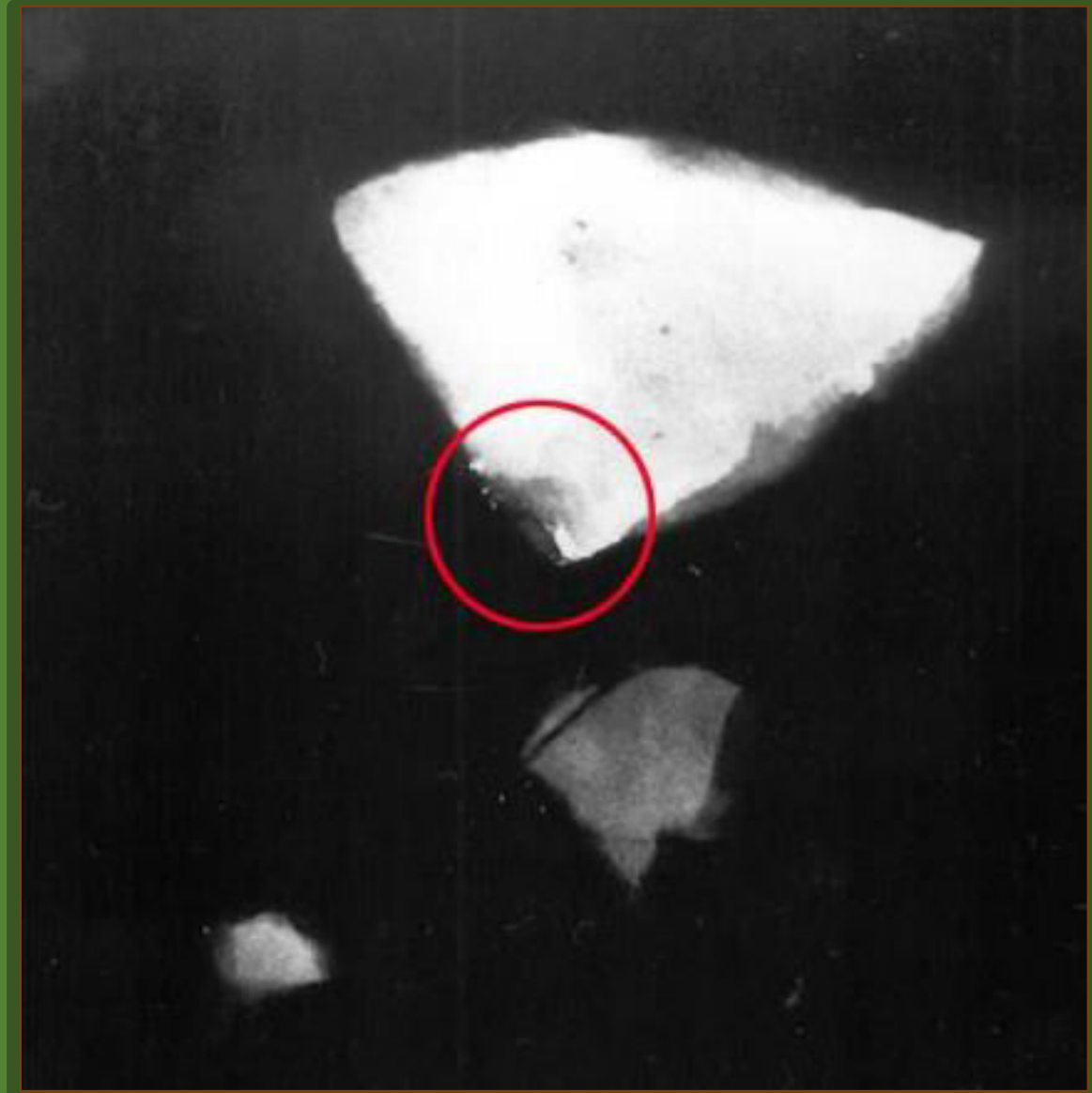
HF Close-
up: Angel's
suture line is
an optical
illusion



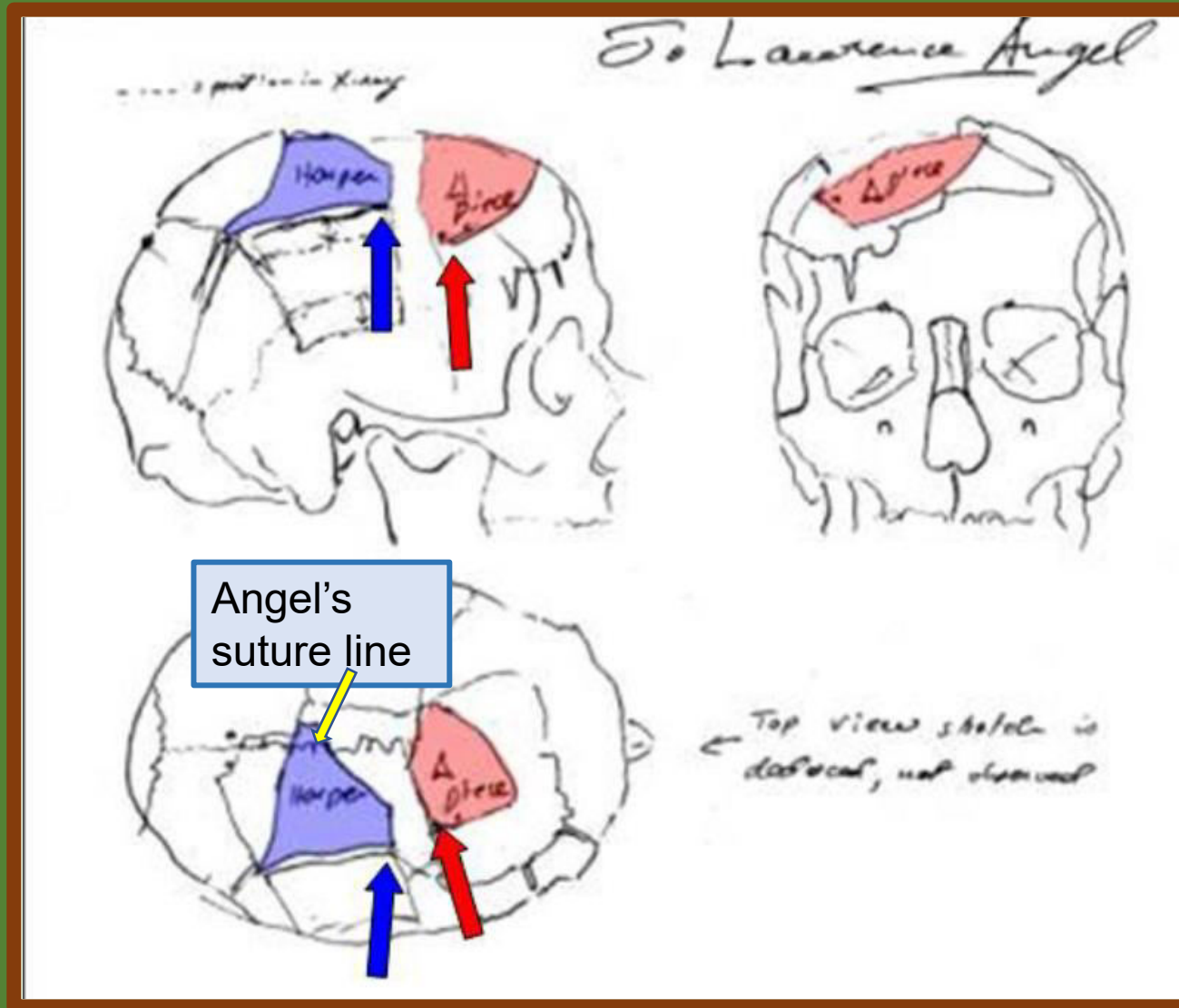
HF Close-up: I was also initially wrong about a suture line



X-ray of the
autopsy
fragments:
metal debris
is circled




HF: Two sites of metallic debris! Did Angel mean to suggest both an entry and an exit?



Actual sentences found in patients' hospital charts

She has been depressed since she began
seeing me in 1993.

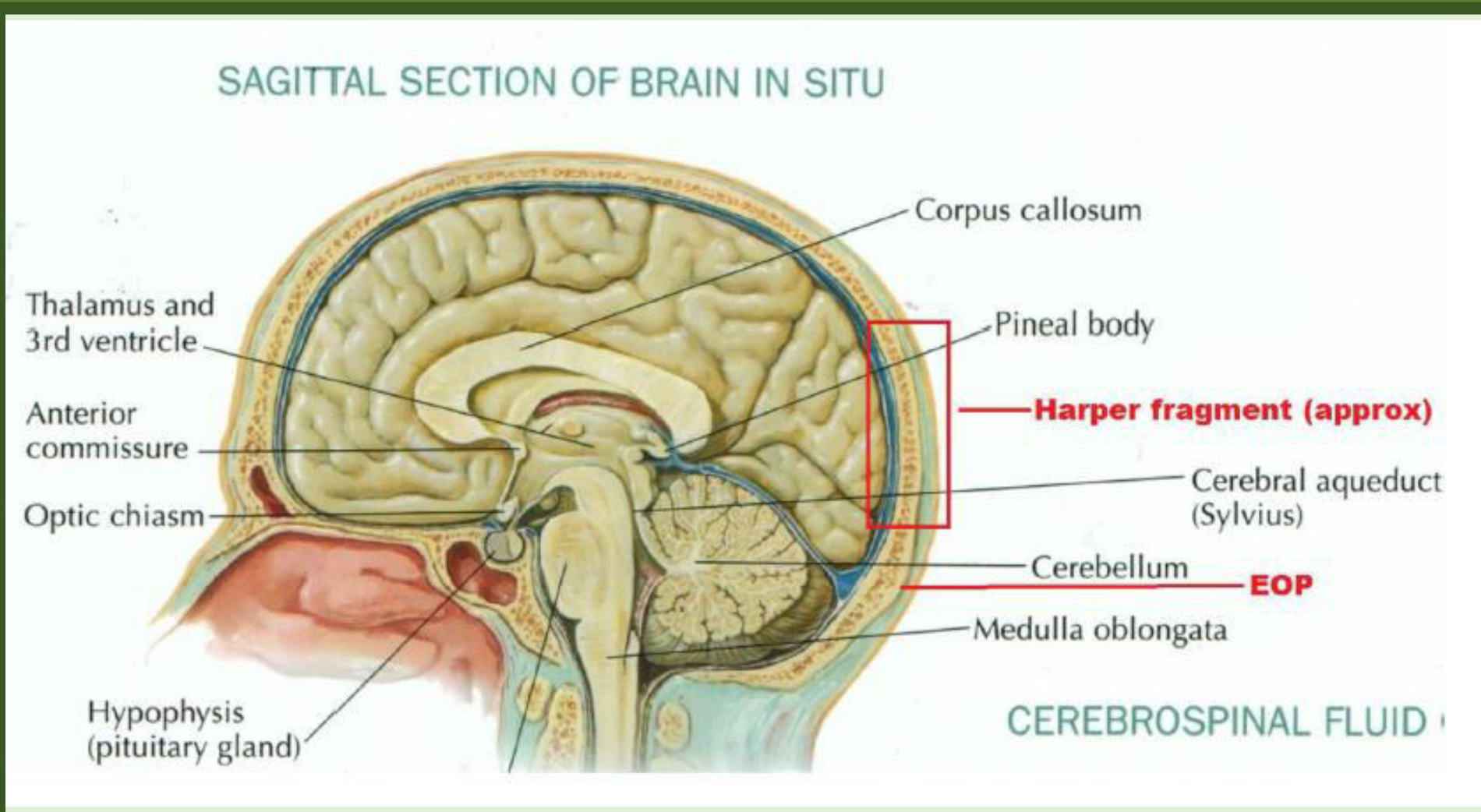
HF—the metallic debris is on the outside!



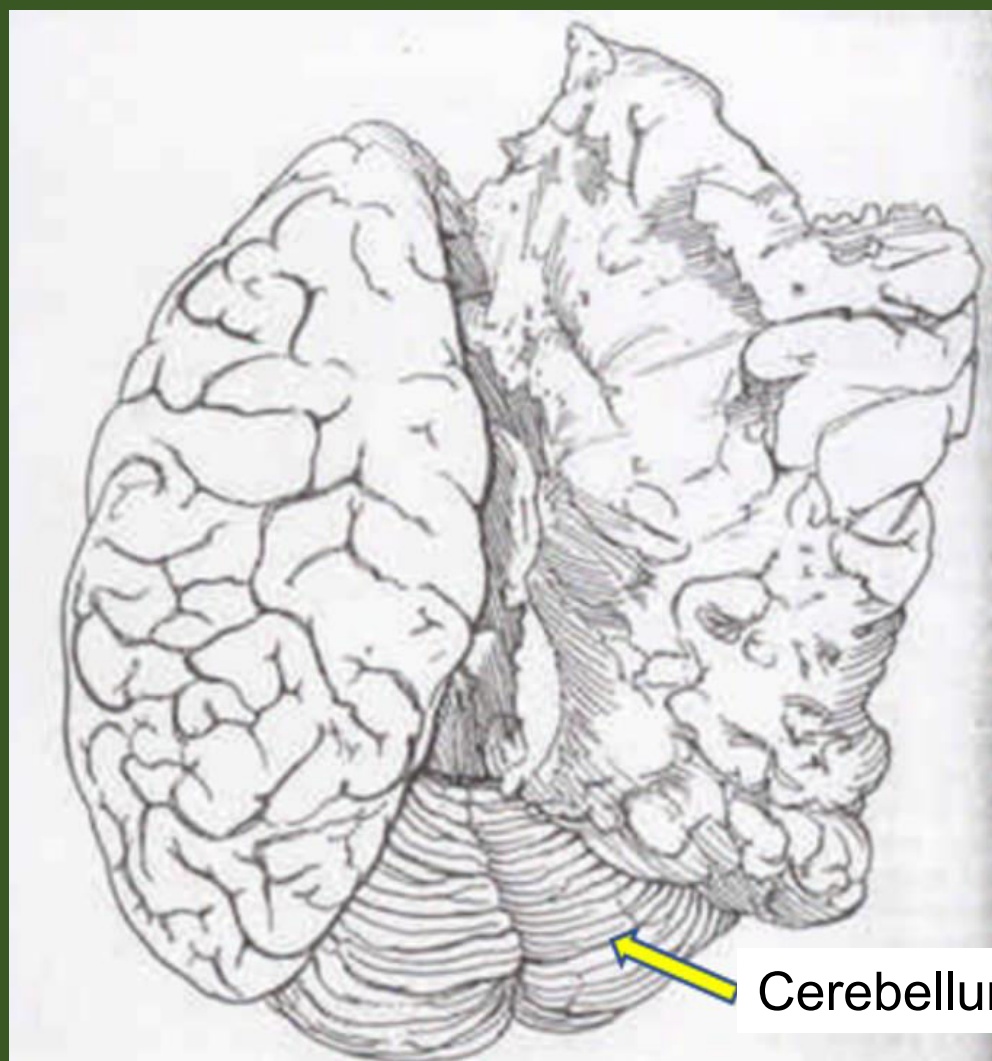
The metallic smear is on the outside

- This clearly implies a bullet entry.
- A parietal site for HF implies a bullet entry near the top of the head. This is not the cowlick area.
- But the parietal supporters never explain how this is possible—just try asking them!
- But if the bullet entered at Humes's EOP site, then everything fits: the smear is naturally on the outside.

Cerebellum was visible via the HF hole



Intact Cerebellum in Brain Drawing



Cerebellum

The dilemma faced by the HSCA

- The HSCA could not admit to a traumatized cerebellum, as McClelland (and many others) recalled. That is because the “brain” photos showed an intact cerebellum.
- So the entry wound absolutely had to be elevated (to the “red spot”)
- And all the witnesses to the big posterior hole had to be discredited

HF: clues
to an
occipital
hole— per
Groden
photos.




Dr. Robert McClelland, Parkland Memorial Hospital:

"The exit wound was in the right, back part of the head, very large. A portion of the cerebellum fell out. Cerebellum extruded from the hole. Perhaps even a quarter of the right-back part of head and brain had been blasted out. I would estimate that 20-25% of the entire brain was missing."



Dr. Paul Peters, Parkland Memorial Hospital:

"He had a large, about seven centimeter, opening in the right occipital-parietal area, and a considerable portion of the brain was missing there, and the occipital cortex, the back portion of the brain, was lying down near the opening of the wound, and blood was trickling out. The wound was here in the occipital-parietal area. We saw the wound of entry in the throat."



Dr. Charles Crenshaw, Parkland Memorial Hospital:

"In the occiput, right here was the large exit wound, about two-and-fourths of an inch, the size of my fist. Here is the wound here in the parietal-occipital area, the size of a baseball. The wound was avulsed."



Dr. William Zedlitz, Parkland Memorial Hospital:

"It was more like so. It was in pieces. It was covered with blood. The back of the head was *not* intact. The bony fragments that were loose, and there was a spongy mass in the center of it, most of it without bone." "A massive head injury to the right occipito-parietal area of his cranium."

John Ebersole, the autopsy radiologist: “big” occipital hole

- He viewed the X-rays—so he knew where bone was missing on the X-rays!
- He told me that he saw a “big” hole in the occiput
- He told the HSCA (1978) that the wound was “occipital”
- After a large bone fragment arrived at the autopsy, he concluded that it must have come from the occiput (so he obviously knew that occipital bone was missing)

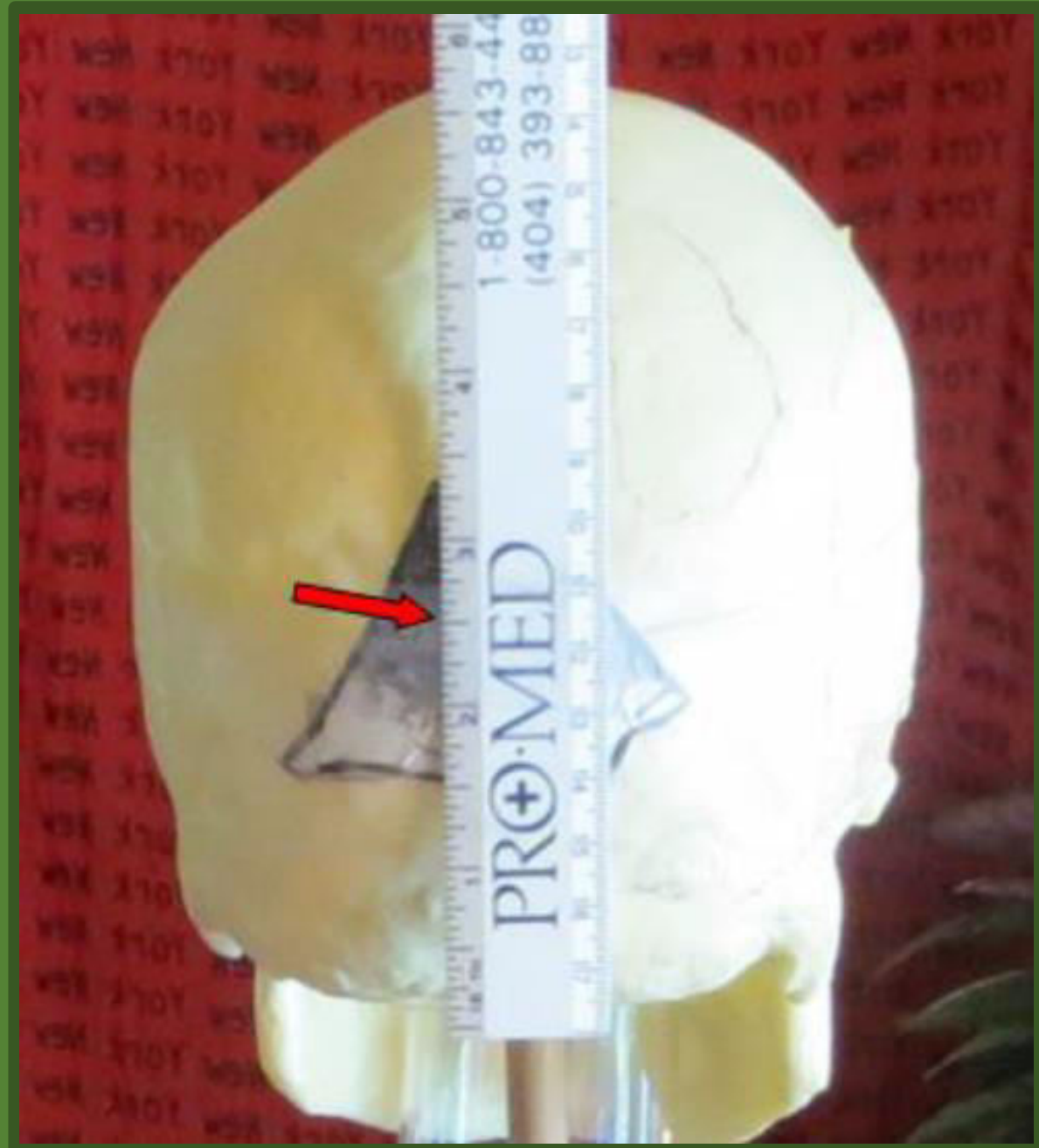
Actual sentences found in patients' hospital charts

Rectal examination revealed a normal size
thyroid.

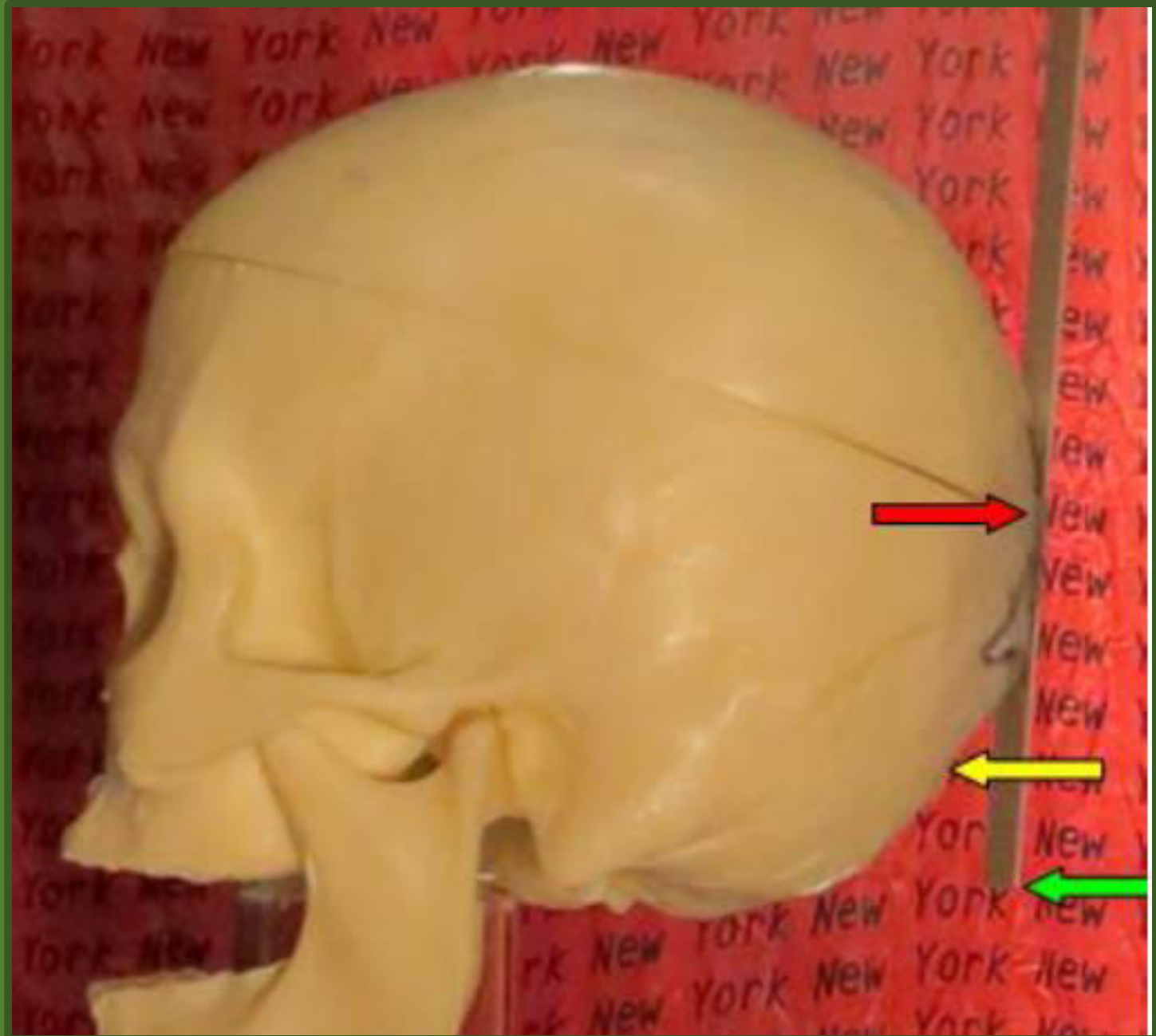
HF: Three Dallas pathologists held HF--and perceived occipital bone

- In 1977 Andy Purdy (HSCA) interviewed Dr. A. B. Cairns
- Cairns recalled that the "...fragment came from an area approximately 2 ½ to 3 inches above the spine area."
- It had the markings of a
 - “...skull fragment from the lower occipital area, specifically: suture and inner markings where blood vessels run around the base of the skull.”
- He also recalled that HF derived from an area close to an entry site.

HF
location
per Dr.
Cairns



HF location
per Dr.
Cairns



1993: Letter to me from Mark Crouch

October 19, 1993 11:54PM

Dear David:

I hope you had a safe trip to D.C. One of my vocations is that I am a contract engineer for several Philadelphia area radio stations. The last several days have been the worst in many month for equipment failure. I have been "on" for nearly 18 hours per day the last 4 days. This has prevented me from getting into the darkroom to print you a really good set of Fox pictures.

I did however have several prints of varying quality in my files so I am forwarding these with my hopes that they are helpful.

Sincerely,



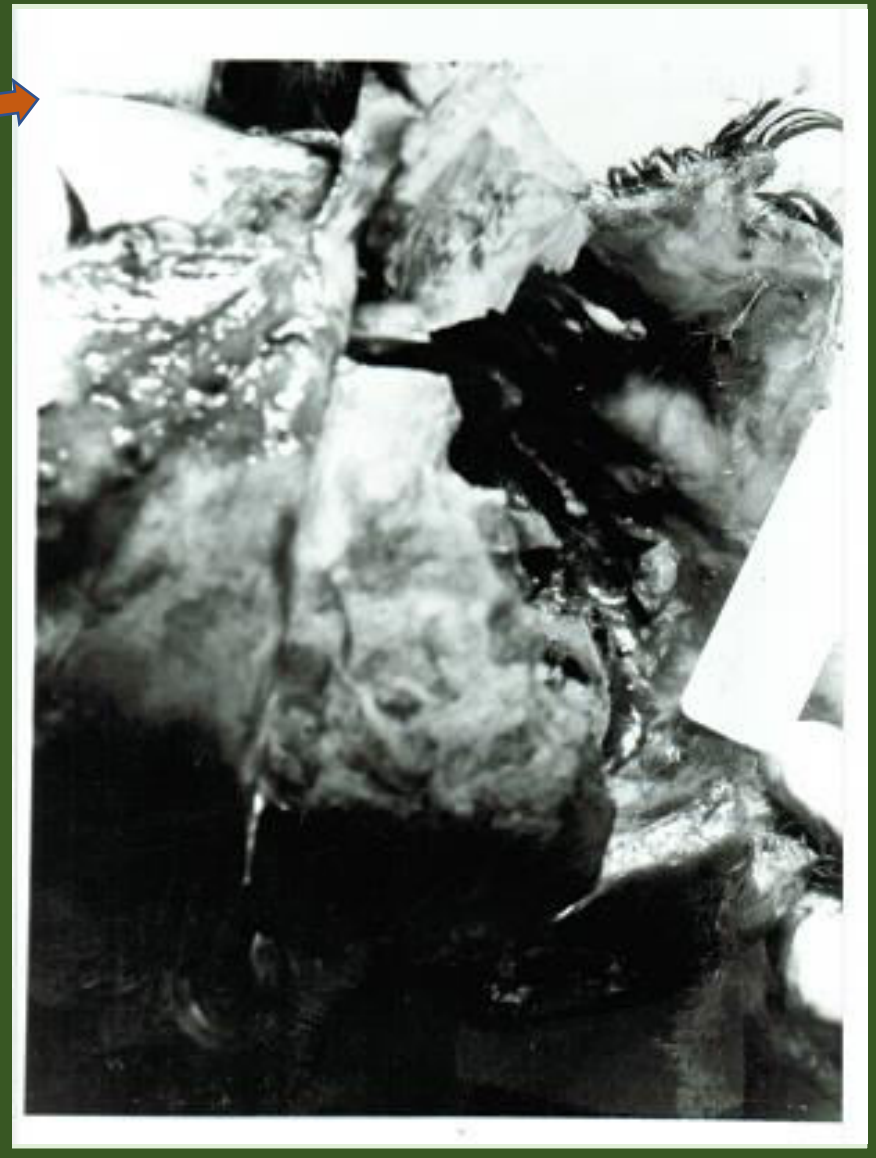Mark Crouch

HF: Clues to an occipital hole—visible fat in F8

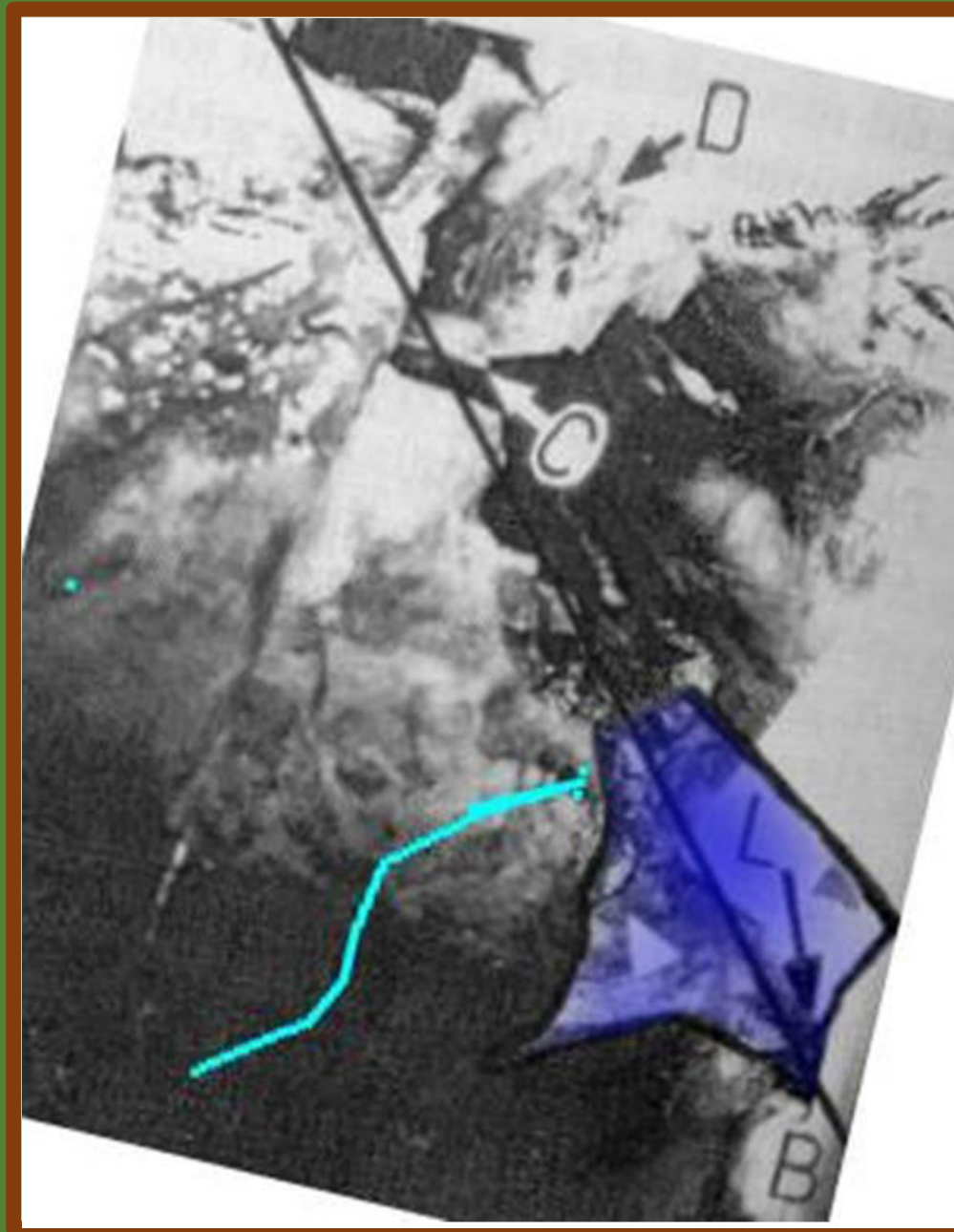
At NARA: Abdominal fat pads, and even a nipple protruding from the chest (on stereo views)

Robert Kirshner, forensic pathologist (ARRB):

definitively oriented. The "yellow spot" in the color photos near the skull was thought to be muscle and fat which had possibly been exposed by the reflection of skin pulled back as a result of the Y-incision during the autopsy. The artifact in the photograph which appears to



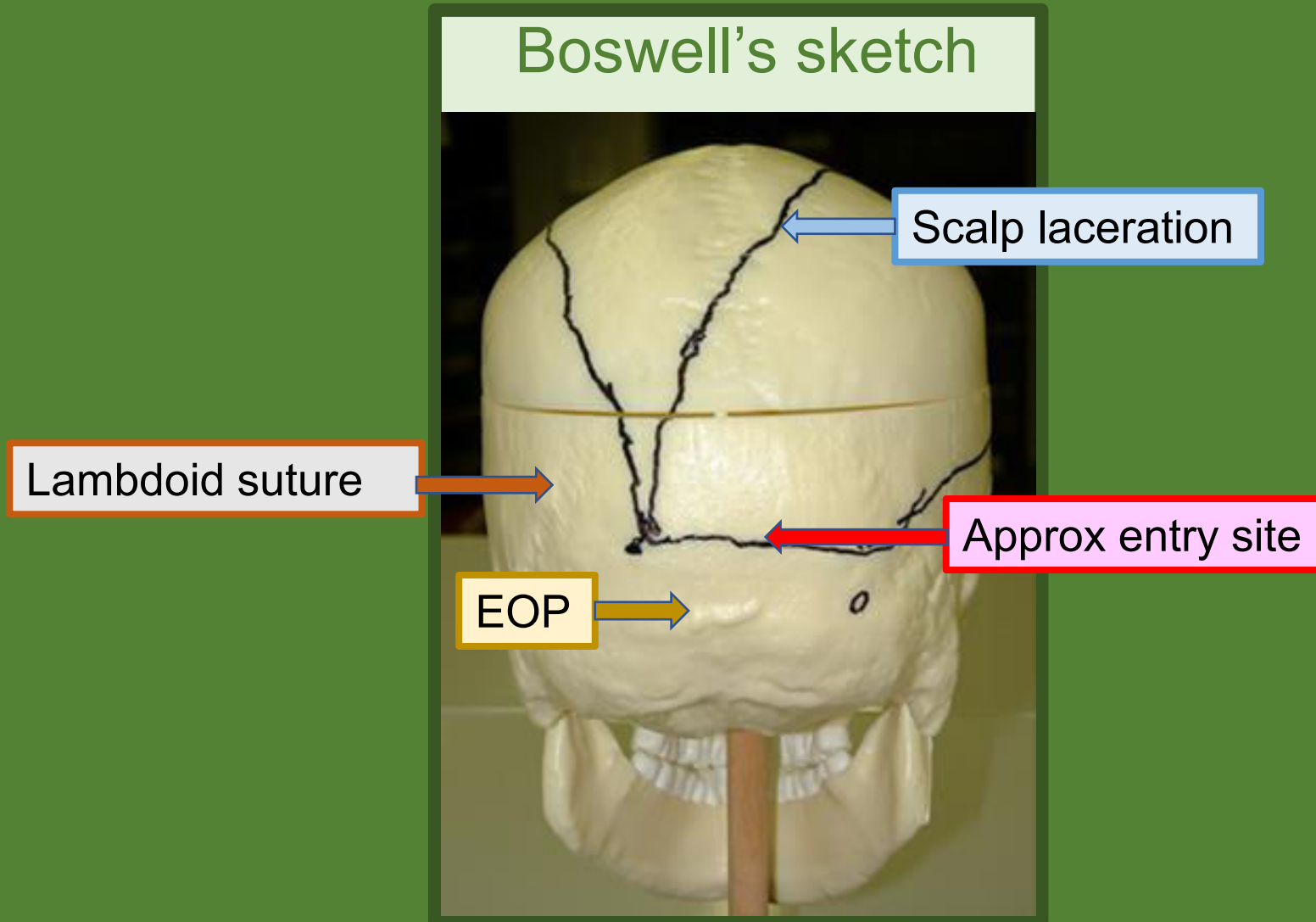
HF Site of
Origin—on
the mystery
photo F8
(per Mantik)



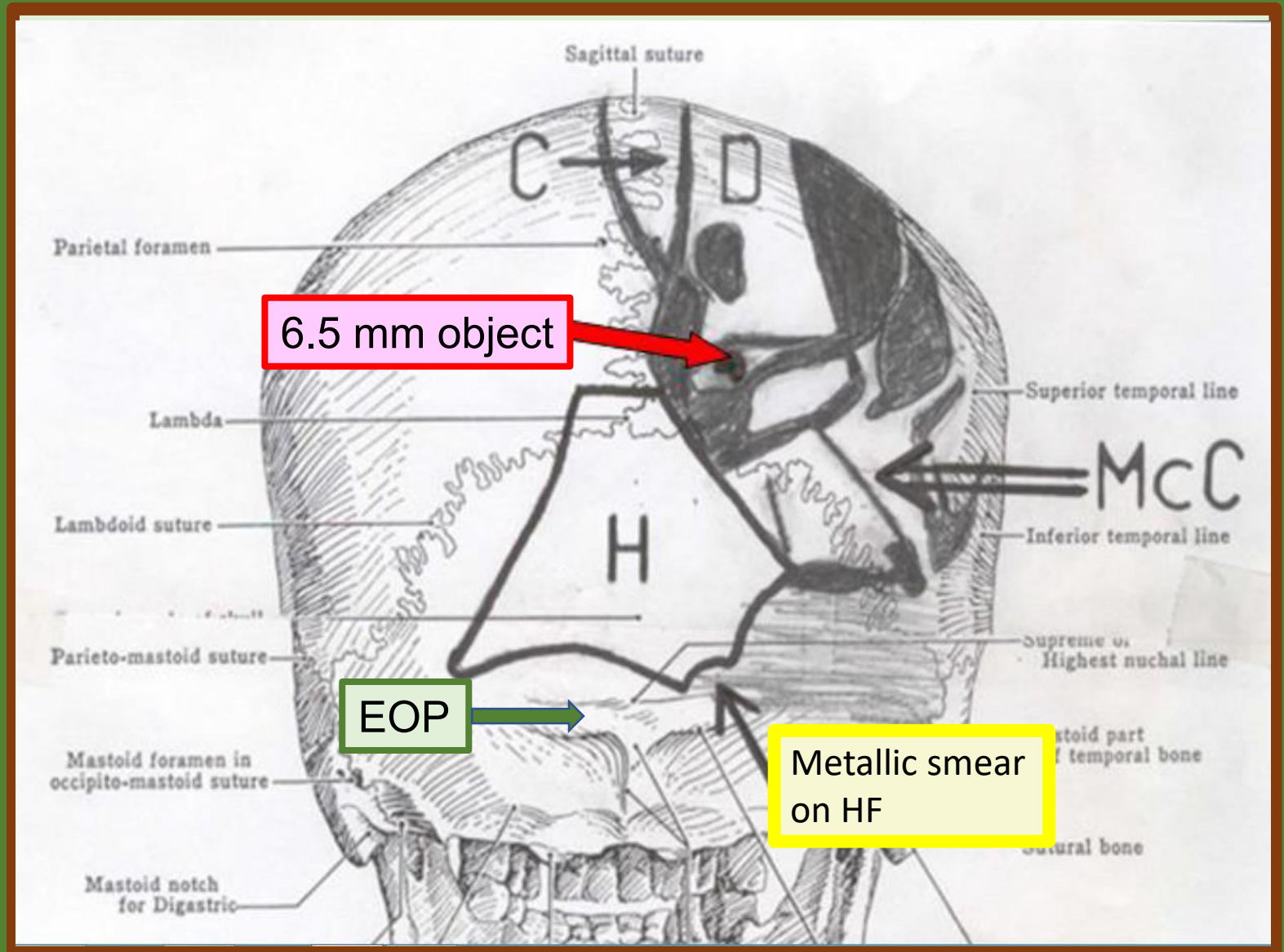
Actual sentences found in patients' hospital charts

Both breasts are equal and reactive to light and accommodation.

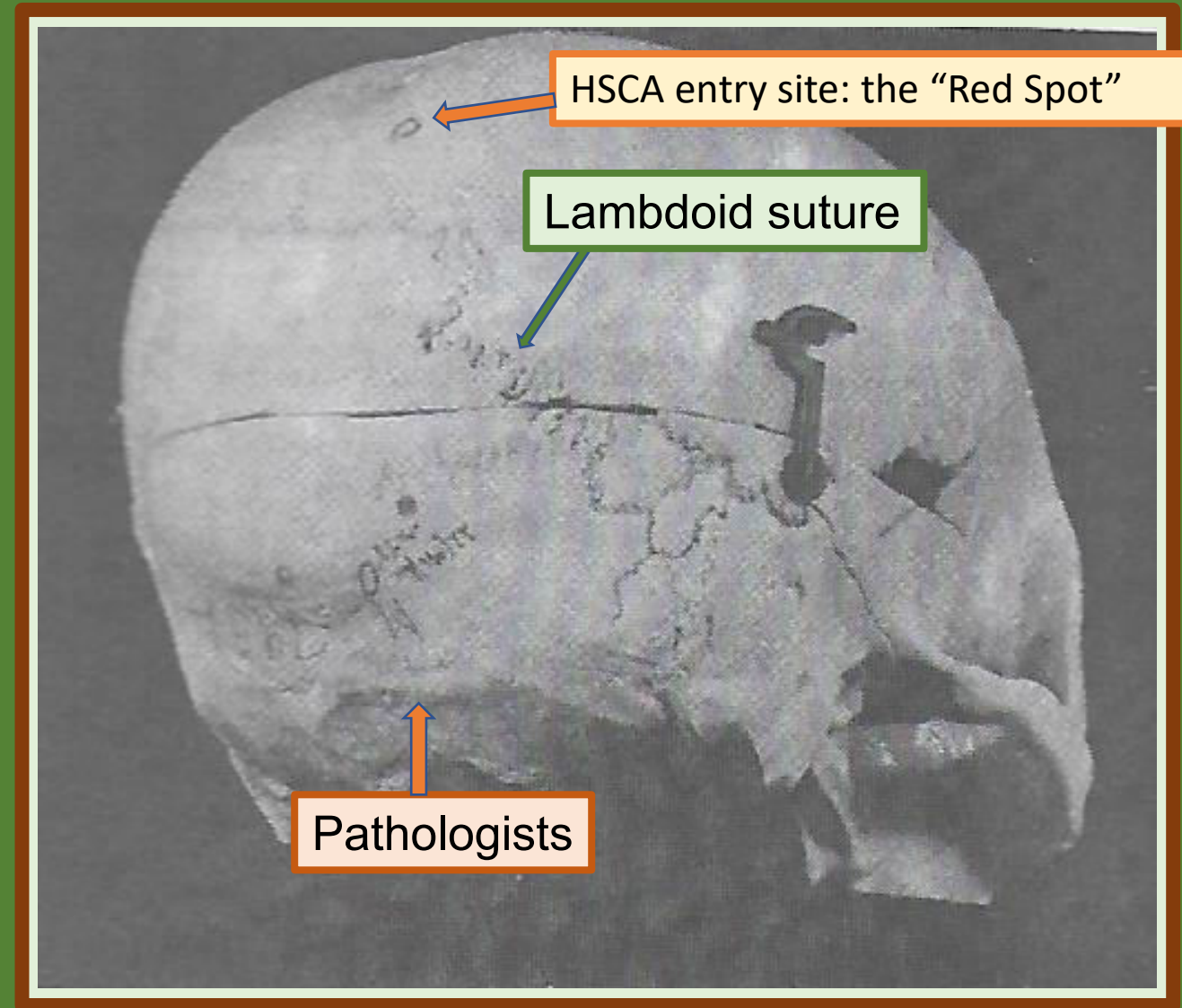
HF: Clues to an occipital hole



Harper (H)
Site of
Origin—as
viewed from
the posterior
(per Mantik)

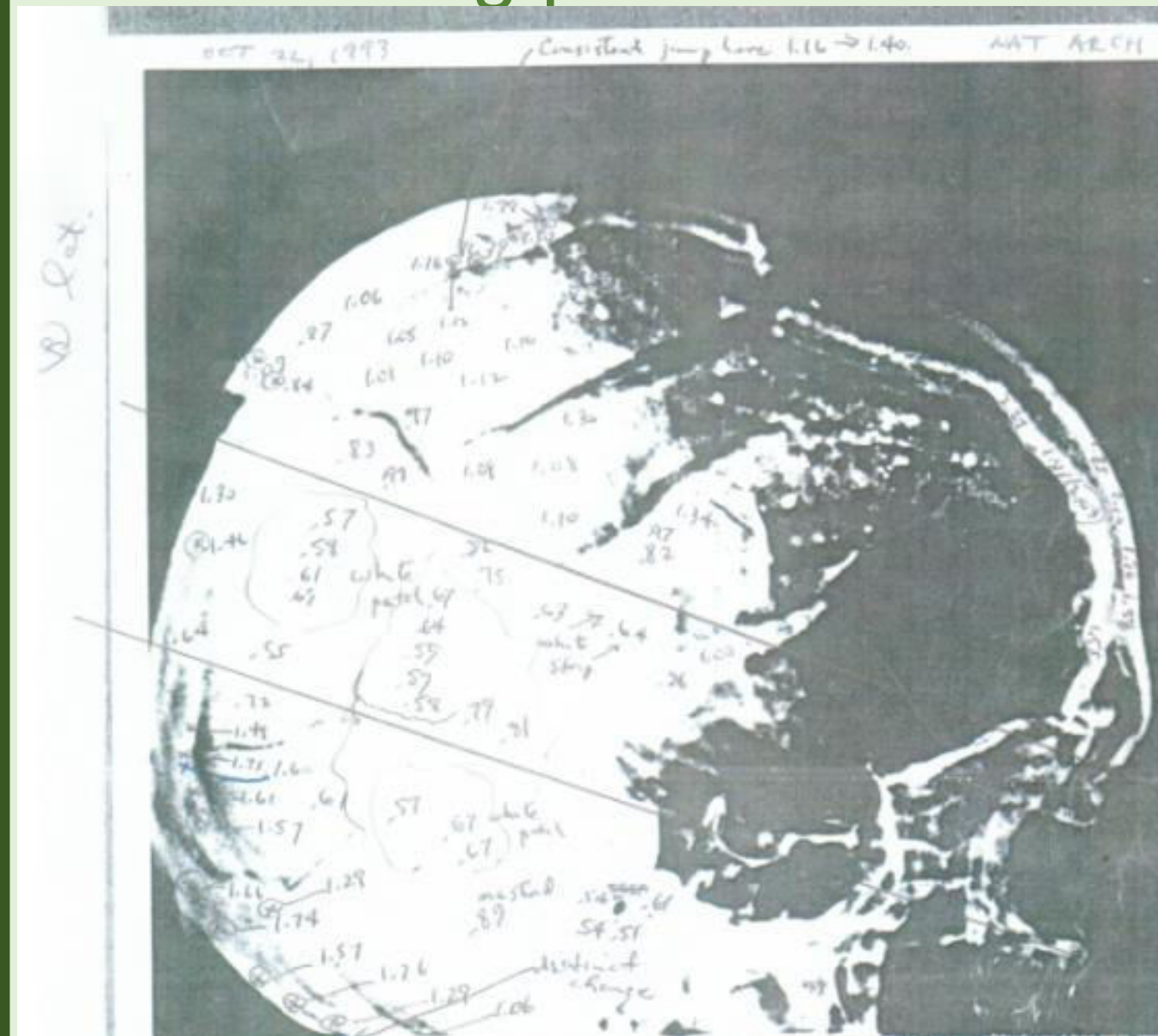


Entry site
(circled)—per
the pathologists
for the HSCA



HF: OD
clues to an
upper
occipital
hole, due to
missing HF

ODs along posterior skull



Actual sentences found in patients' hospital charts

The patient was to have a bowel resection.
However, he took a job as a stockbroker
instead.

Three Headshots

Figure 36. The three headshot scenario.

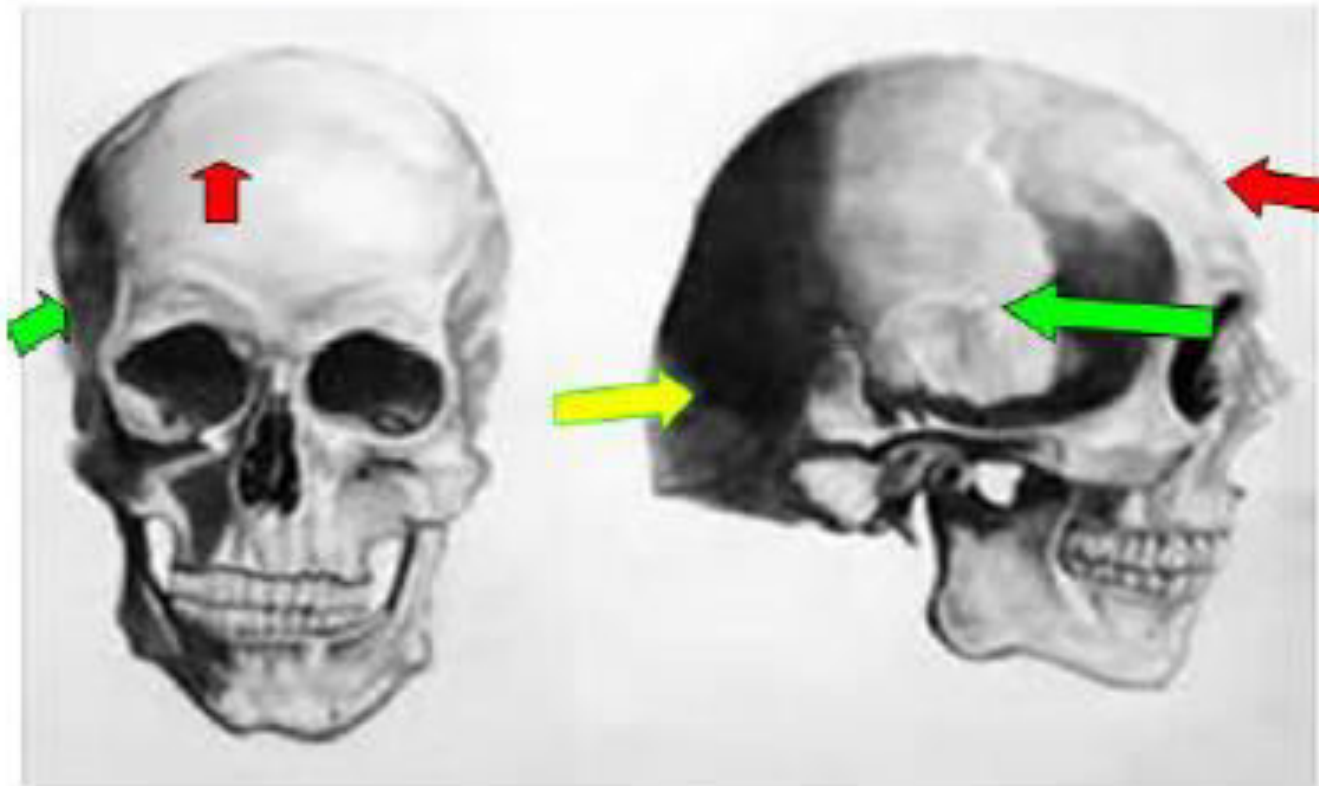
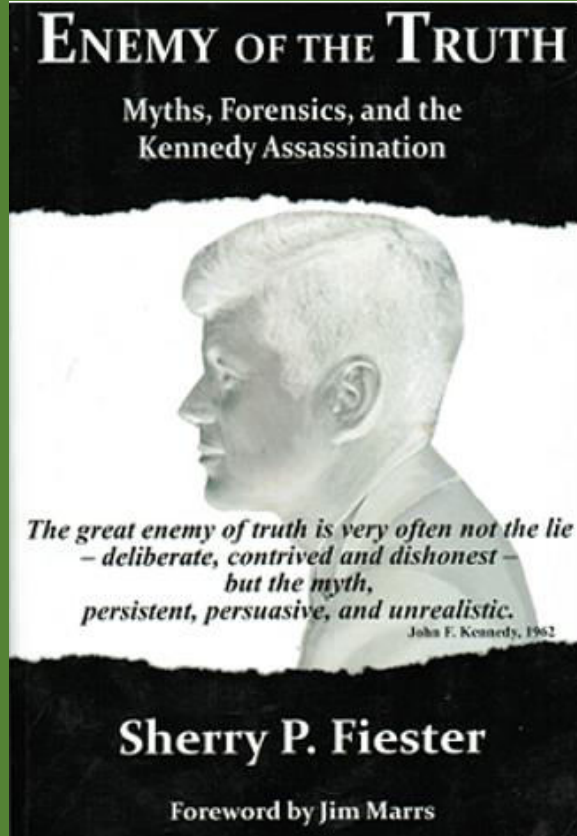


Figure 36. Schematic illustration of the three headshots. Entry sites are only approximate. Each color defines a different shot.

Sherry Fiester: Only one headshot!



“Current forensic research [not cited] supports a single gunshot originating in front of the President, and front is not the Grassy Knoll. All other explanations are myths....”

- My Fiester review is at *Kennedys & King*
- Just Google: “Fiester” and “Mantik”

Three Headshots: Table 1 (e-book)

Table 1. Summary of Three Headshots

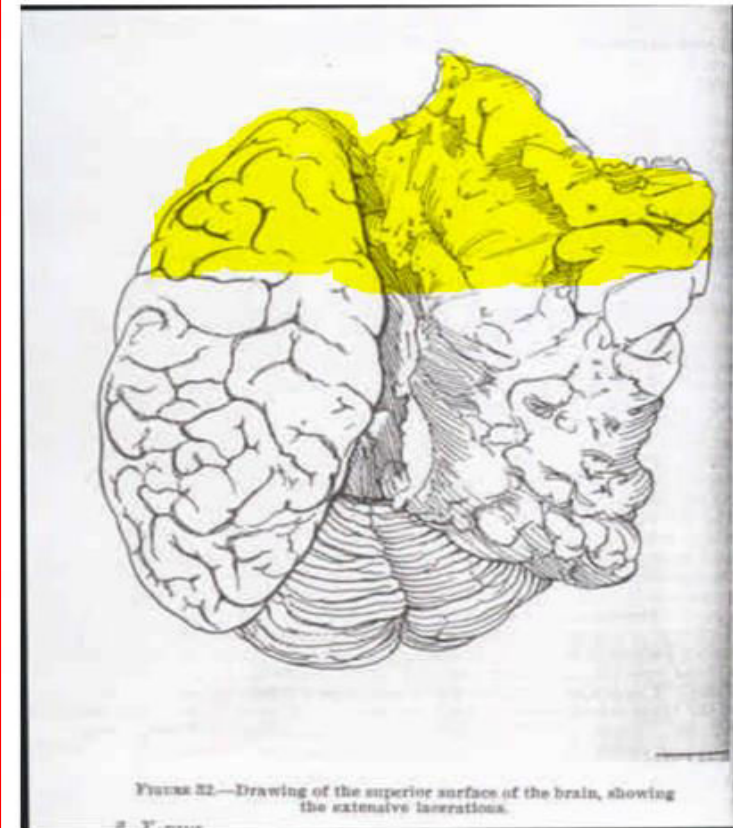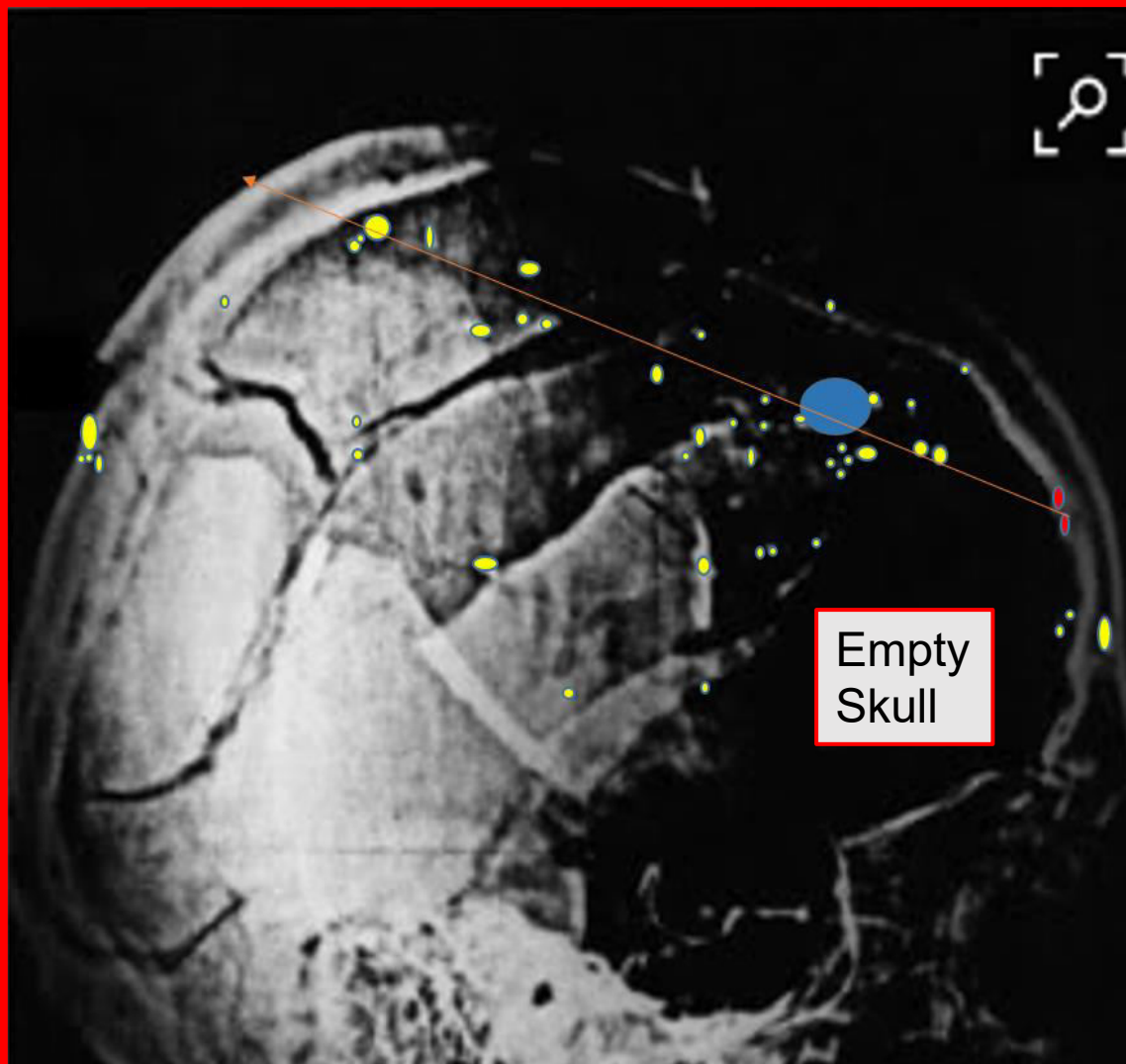
Shots

Evidence	#1 (EOP)	#2 (forehead)	#3 (oblique)	#4 (ricochet)
Debris on hood ornament	✓			
7x2 mm fragment	✓			
Leftward head jerk	✓			
HF in occiput: smear near EOP	✓			
Metallic trail on X-rays		✓		
Witnesses to forehead wound		✓		
Forehead incision		✓		
Pre-autopsy surgery	✓		✓	
Debris flying forward	✓		✓	
Debris to left rear			✓	
HF ejection			✓	
Occipital hole			✓	
Witnesses to wound near right ear			✓	
Belmont memo			✓	
James Tague wound				✓
Metal fragment in left scalp				✓
Back wound				✓
Metal fragment at back of head				✓
Small metallic particles in Figure 9				✓
Witnesses to bullet hitting street (cf. Z-144)				✓

HF Conclusion: Some of the 15 clues to the occipital origin of the Harper Fragment

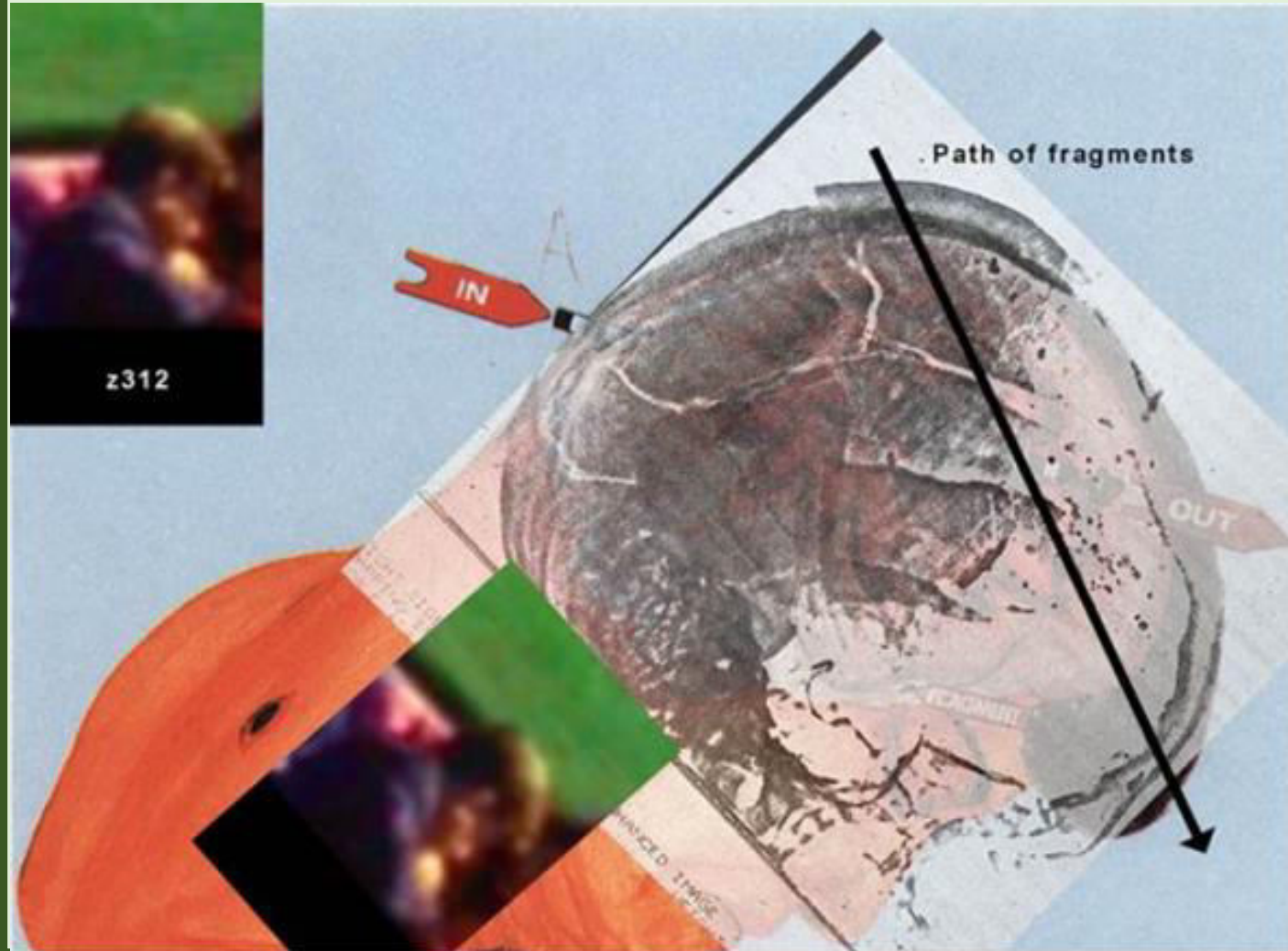
1. Three Dallas pathologists
2. John Ebersole, MD
3. Numerous Parkland witnesses
4. Eight Bethesda MDs
5. Cerebellum seen (as traumatized)
6. Autopsy Report
7. Boswell sketch—and statement
8. Metallic smear was on the outside
9. Mystery photograph (F8)
10. Optical density data

A Few More Paradoxes



Ida Dox prepared this drawing for the HSCA. It is the only image in the public record. The yellow tissue is absent on the lateral X-rays.

JFK lateral X-ray superimposed on Z-312, as composed by David Josephs



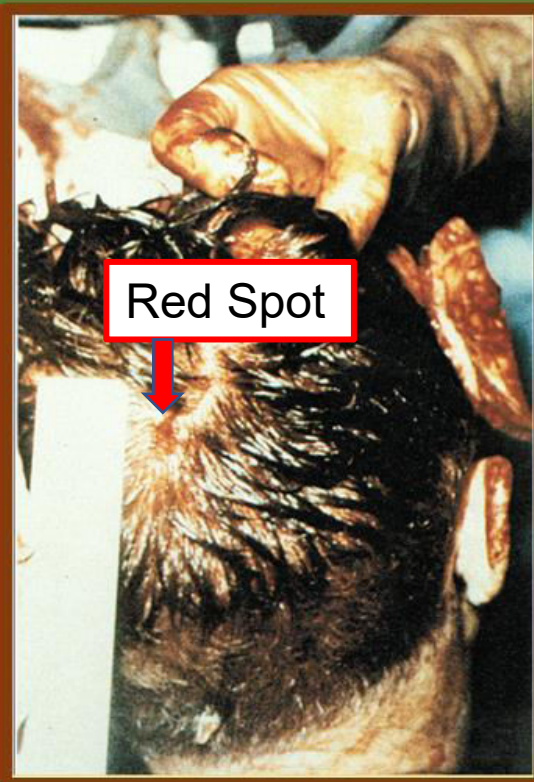
More
Paradoxes

Actual sentences found in patients' hospital charts

Patient was seen in consultation by Dr. Brooks, who felt we should sit on the abdomen. I agree.

Yet More Paradoxes

1. How does this clean scalp soil this shirt?
2. How does this Z-317 "wound" soil this shirt?



Six Mantik References

1. Twenty Conclusions after 9 Visits (2003):
<https://assassinationresearch.com/v2n2/pittsburgh.pdf>
2. JFK Lancer Lecture (2009—on how to alter 1963 X-rays):
<http://assassinationofjfk.net/jfk-skull-x-rays-evidence-of-forgery-david-mantik/>
3. THE JOHN F. KENNEDY AUTOPSY X-RAYS: THE SAGA OF THE LARGEST
“METALLIC” FRAGMENT (2015):
<https://www.journals.ke-i.org/index.php/mra/article/view/177/78>
4. Houston Mock Trial (2017):
<https://statick2k-5f2f.kxcdn.com/images/pdf/david-mantik-houston-2017.pdf>
5. JFK Assassination Paradoxes: A Primer for Beginners (2018):
<http://escires.com/articles/Health-1-126.pdf>
6. The Mantik Website (courtesy of Bernard Wilds in the UK):
<http://themantikview.com/>