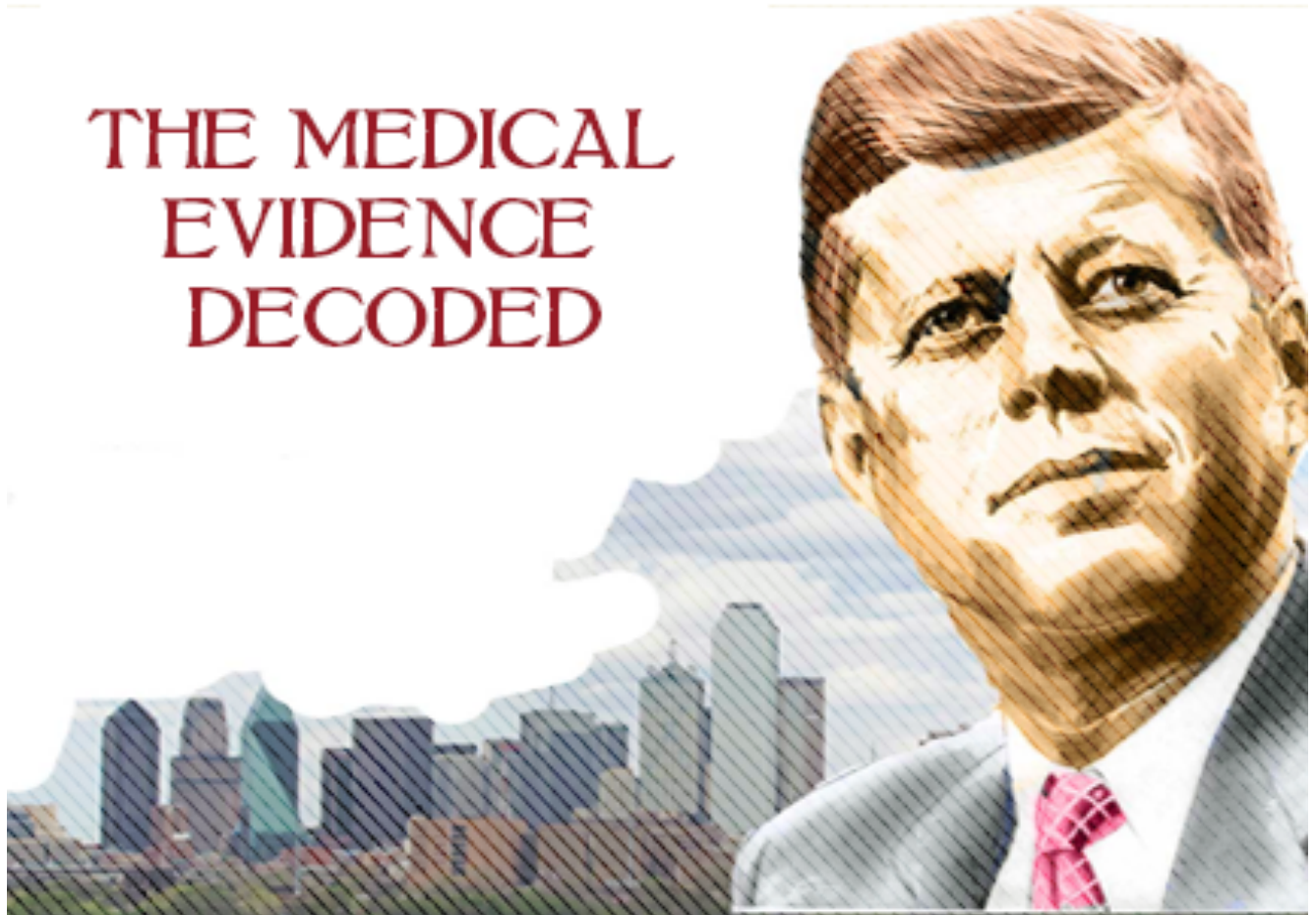


THE MANTIK VIEW

THE MEDICAL
EVIDENCE
DECODED



THE MEDICAL EVIDENCE DECODED

David W. Mantik, M.D., Ph.D. [THE MANTIK VIEW](#)

[Editor's note: After securing permission from the Kennedy attorney, Burke Marshall, Dr. Mantik visited the National Archives on at least seven occasions to review (and take measurements on) the autopsy photographs, the autopsy X-rays, JFK's clothing, and the ballistic evidence. Mantik's background as a radiation oncologist (certified by the American College of Radiology), together with his Ph.D. in physics (with a thesis in X-ray scattering) from the University of Wisconsin, make him uniquely qualified to address the conundrums of this exceptional case. No other individual with such credentials has ever reviewed this data. For the X-ray work, in particular, a background in medical physics (with an emphasis on X-rays) is essential. These skills would not be found in the ordinary radiologist, nor would a medical physicist, by himself, be competent to address the decisive medical issues that proliferate in this case. These talents of physician and physicist, must be combined in a single individual, as fortuitously occurs with David W. Mantik. This case has long been waiting for such a synthesis.]

I found the minions of the law, the agents of the FBI, to be men who proved themselves not only fully capable, but also utterly willing to manufacture evidence, to conceal crucial evidence and even to change the rules that governed life and death if, in the prosecution of the accused, it seemed expedient to do so. -Gerry Spence

Introduction

Allegations of missing, mysterious, or even manipulated autopsy photographs, burned drafts of the autopsy report, altered X-rays, and the media to the conspiracy fringes usually ascribes a substituted brain. However, these admissions and intimations have recently emerged from an official review of the JFK assassination. Repeat depositions of the three autopsy pathologists and interviews with the two autopsy photographers (and many other medical personnel besides) offer fresh insights into anomalous events following 22 November 1963.

In particular, a new interview with a darkroom technician who developed autopsy photographs, and new revelations from JFK's White House photographer, his family, and a close colleague, all offer further glimpses into irregular activities (related to the autopsy) immediately after the assassination.

All of these reports derive from the Congressionally Mandated Assassination Records Review Board (ARRB), which was created by Congress in the surge of public interest generated by Oliver Stone's movie, JFK, and which ceased its operations on 30 September 1998. It is noteworthy that the ARRB itself cited ongoing doubts about the Warren Commission:

Doubts about the Warren Commission's findings were not restricted to ordinary Americans. Well before 1978, President Johnson, Robert Kennedy, and four of the seven members of the Warren Commission all articulated, if sometimes off the record, some level of skepticism about the Commission's findings (Final Report of the ARRB, 1998, p. 11).

This essay focuses on the new medical evidence. Based on remarkable paradoxes in multiple areas, it is apparent that a series of extraordinary events many illegal, occurred in the immediate aftermath of the death of JFK.

This study relies partially on two essays in the present volume, one by Gary L. Aguilar, M.D., and one by Douglas P. Horne. Horne worked at the ARRB for its entire lifetime (under then executive Director Jeremy Gunn) and was the primary staff member (apart from Gunn) responsible for the medical evidence. Since these authors provide details not repeated here, their essays should also be read.

The Chasm that Divides the Partisans

Ever since the early years of this case, partisans have argued fiercely for their own views, some insisting that Oswald was the sole protagonist, while others insisted that a wide conspiracy implicated the CIA, the Mafia, anti- Castro Cubans, and possibly even wealthy Texas oilmen. With the passing of the years, and especially with the new releases of the ARRB, the wide chasm that divides the partisans is now easy to identify: it is the credibility of the evidence, not just the medical evidence, but also the evidence against Oswald. The present essay, however, is confined solely to the medical and scientific arena and shall say nothing useful about the Oswald evidence. [Editor's note: See, however, the study of Jesse Curry's JFK Assassination File elsewhere in this volume.] A strong argument can now be made that the medical evidence cannot be taken at face value and that prior conclusions based upon it are not reliable. In a very real sense, the discussion must begin anew, almost as if the crime had been committed last week.

In the opening quotation, Gerry Spence (From Freedom to Slavery 1995, p. 27 describes his own experiences with the FBI in the matter of Randy Weaver of Ruby Ridge, Idaho. The JFK case often seems hauntingly similar to Spence's own experiences. For example, in the Ruby Ridge affair Spence even notes a second "magic" bullet (1995, p. 50).

If the evidence in the JFK case is merely accepted at face value, then the conclusions are rather trivial. The rookie Scotland Yard inspector can easily solve this case; it was Oswald alone. The real challenge is to assess the credibility of the evidence. Vincent Bugliosi, [1](#) the former Los Angeles County prosecutor of Charles Manson (and winner of virtually all of his other cases) still maintains that Oswald did it. He is even writing a book that will attempt to prove this. I have advised him that if he ignores this fundamental issue of evidence reliability then real communication between partisans across this chasm is unlikely to be advanced.

In analogy to Gerry Spence's own experiences with the FBI, many private investigators, based on diverse lines of detailed research, believe that something is deeply, and tragically, wrong with the JFK evidence. My own analysis of the autopsy skull X-rays, based on hundreds of point-by-point measurements performed at the National Archives over multiple visits, indict the X-rays regarding several critical features, in a way that no prior investigation could do (James Fetzer, Assassination Science 1998, pp. 120-137). Short of X-ray alteration, these findings remain a deep, and probably insoluble, mystery, a matter to which I shall later return.

Oswald's post-mortem conviction by the Warren Commission relied rather little on the medical evidence. In their final report, the pathologists merely repeated what they had

been told before the autopsy: namely that the fatal shots had come from the rear and that the sole assassin was already in custody. Based on the autopsy alone, they could not possibly have known who had fired the shots, nor, short of reviewing the photographic evidence from Dealey Plaza (which they did not do), could they have speculated meaningfully about the origin of the shots. This essay, being likewise largely confined to the medical evidence, can reach no meaningful conclusion about Oswald's ultimate guilt or innocence. It can, however, demonstrate in several significant ways how the medical evidence was used to frame Oswald. It can also strongly suggest that two successful shots came from the front.

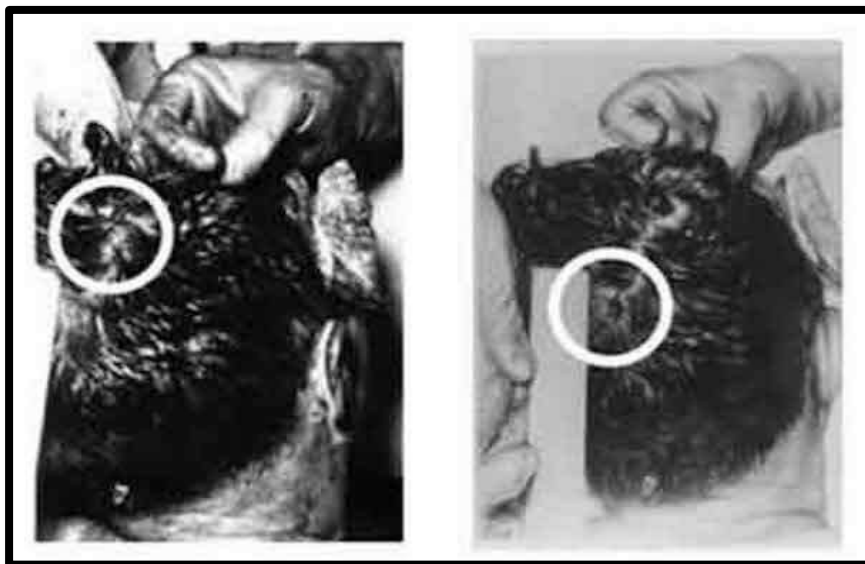


Figure 1. Posterior Head Photograph from the Autopsy. No eyewitness reported what is seen here. Eyewitnesses recalled an orange-sized hole at the right rear. No one saw the red spot (the supposed entry wound) near the top of the ruler, and no one knew what the white spot (near the bottom, just above the hairline) represented. Unlike the Ida Dux drawing (right), the actual wound is not visible in this photograph (left), and no other photographs show it either.

The pathologists concluded that only two shots struck JFK, both from the rear. They claimed that one struck the back of the head just above the right hairline) and that the only other successful shot hit the upper back. They insisted on this again when interviewed by Dennis L. Breo ("JFK's death, the plain truth from the MDs who did the autopsy," *Journal of the American Medical Association*, May 1992, pp. 2794-2803). Their conclusion of two successful shots from the rear was reasserted by the House Select Committee on Assassinations (1977-1979), albeit with one highly significant change: the headshot was moved up by 10 cm so that it now coincided with the "entry" wound on the photograph (Figure 1). (Author's note: I shall use quotation marks around "entry," regarding this specific site, because it is not an authentic wound; the evidence for this is presented below.)

Although the House Select Committee on Assassinations (HSCA) concluded that there had been a probable conspiracy (based on acoustic data that arrived at the end of its work), in their view this additional shot from the grassy knoll had missed, thus leaving it beyond the purview of the medical evidence. The HSCA's primary conclusion of one

headshot at a higher location was based critically on posterior head photographs. Although the lateral X-ray was proposed as a supporting pillar for this conclusion, I shall demonstrate later how the new evidence has shattered this pillar to bits. So, although Oswald's accusers agreed that he had hit JFK's head, they nevertheless have disagreed by 10 cm (four inches) on where that bullet entered, an astonishing discrepancy of over half the width of the skull. It is as though a surgeon, operating on a melanoma of the eye, had removed the right eye instead of the left, his error in distance would have been less than that supposedly made by not one, but by three, qualified pathologists.

The ARRB

This was the state of the medical evidence when the ARRB took center stage in 1994. Contrary to prior inquiries, the ARRB was not charged with reaching any conclusions. Its mandate was merely to locate and to release evidence. Fortunately, the ARRB also deposed witnesses, those newly discovered as well as some previously deposed. It is largely these new interviews (along with some releases of previously secret interviews) that have radically altered the complexion of this case. Indeed, the weight of these new findings strongly points toward a conspiracy in the cover-up, one that involved elements of the government itself. The ARRB, however, did not leave the impression either in its final report (Final Report of the Assassination Records Review Board, US Government Printing Office, 1998), in its press releases, or in its occasional media interviews, that the medical evidence had thrown a live hand grenade into this case. In fact, rather little was said about the medical evidence. It is important to recognize, however, that there is an explanation for this peculiar silence, as Horne explains. He routinely prepared questions for the medical witnesses and assisted with the interviews and depositions. In view of the panorama of new (and often unexpected) medical evidence, of which both he and Jeremy Gunn were acutely aware, Horne proposed detailed briefings for the five Board members. According to Horne, [2](#) this was never done in more than a perfunctory manner. The primary reason for this disregard was that the Board had little patience with the medical evidence. As a result, they remained largely ignorant of the surprising evidence uncovered by their own staff. Their final summary, which says rather little about the medical evidence (especially those issues discussed here), bears clear witness to this state of affairs.

It should not surprise us that a Board with little medical background adopted an aloof attitude toward the medical evidence. The Board was, after all, not under any mandate to assess this evidence nor to draw any conclusions from it. Indeed, during their tenure, more progress was made in the medical evidence than in both of the preceding investigations, i.e., those performed by the Warren Commission and by the HSCA. As Harrison Livingstone has pointed out, a major reason for this improved performance was that both Gunn and Horne took seriously the possibility that the medical evidence had been altered. Furthermore, there is little doubt that serious effort is required to master the medical evidence. In fact, most Board members had full time positions elsewhere and the Board met only once or twice per month. At these meetings, there was much new evidence to review beyond the medical area. It is quite likely therefore that the Board did not have detailed knowledge of these matters.

To obtain further insight into the Board's knowledge of and attitude toward the medical evidence, I drafted a two-page questionnaire (of 25 questions) on the medical evidence. These questionnaires were sent to the former Chairman of the ARRB, John Tunheim, who agreed to act as intermediary, first by forwarding the questionnaires to the individual members and then by returning their responses to me. These questions sought to assess (to a limited degree) the Board's knowledge of and interest in the medical arena. It also directly asked them to assess the overall importance of the medical evidence for the JFK assassination. At the time of publication, some months later, no responses had been received, despite the fact that a deadline had been imposed. ³ This lack of response, from all five Board members, is, *prima facie*, a fair reflection of their attitude toward the medical evidence.

The Predicament of Prior Official Reviewers

In a very real sense, the case made by the pathologists, resting as it did on an actual examination of the body, brain, and authentic X-rays, was based on more solid ground than subsequent forensic reviews, which had no access to any of this fundamental data. Later reviewers were confined solely to photographs, second-hand pathologic data, and, as I shall argue, X-rays that were altered in critical respects. Despite this patently unorthodox database, virtually no other forensic case is so limited ⁴ advocates of the lone gunman theory have recited (in almost mantra like fashion): "X forensic pathologists and Y radiologists have reviewed this material over Z years and every one of them [save for Cyril Wecht, M.D., J.D] agrees with two shots from the rear."

The proper response to this ritual is to emphasize that it takes no great skill to reach this conclusion based on the available photographs of the back of the head... they really leave no other option. Shown these photographs, the man on the street could do just as well... and at much less expense! Even he can see the famous red spot on the photographs of the back of the head (Figure 1). But in this case, an additional question needs to be asked: if these particular pieces of photographic paper were lost, would the evidence for a high, posterior headshot then be merely paper thin?

On the other hand, if lost photographs (which are well substantiated by the newly interviewed protagonists) that display a large hole in the back of the head were suddenly discovered how would the argument proceed then, and what would the traditional experts then conclude? In fact, several, critical, new witnesses report having seen precisely such photographs and, as I argue in the Postscript, one of these photographs even exists in the current collection. New evidence now permits a surprisingly thorough analysis of all of these questions, as explored below.

Ultimately, the argument from the medical evidence must rely on the autopsy findings (of the body and the brain), the photographs, and the X- rays. The single gunman theory can be effectively challenged only if this database is defective. [Editor's note: The single gunman theory is merely a hypothesis, which appears less and less plausible with each new piece of medical or scientific evidence. It is long past time to stop denigrating proponents of conspiracy as "conspiracy theorists," as though they were devising fictions. It is the supporters of The Warren Report (1964) who now appear preoccupied with Procrustean fact bending.] The primary goal of this essay is to summarize the overwhelming evidence that this is the situation that faces us today. I shall argue

that none of the fundamental medical evidence, neither the brain photographs, nor the photographs of the back of the head, or the autopsy X-rays is entirely reliable. It is finally possible now to explain precisely how this evidence has led us astray.

Although this situation is unique in the annals of forensic medicine, nonetheless, the evidence for this view is now extremely robust, particularly with the new releases. Furthermore, due to a modest stroke of serendipity in timing, my own work with the X-rays, which was performed immediately prior to the advent of the ARRB, has now been shown to be thoroughly consistent with (and even predictive of) the ARRB's new evidence. This X-ray work led to a list of critical questions about the medical evidence questions that were actually put to all three pathologists while under oath by the ARRB, with replies that were sometimes embarrassing (for the pathologists) and sometimes unexpected (for lone gunman advocates). [Editor's note: Interviews with Boswell and Humes are excerpted in Appendix F and Appendix G.]

After the medical evidence has been reviewed, one question still remains: what role did the pathologists play in this escapade? Were they merely incompetent, or did they knowingly cover-up (or even lie) at critical points along the way? The new evidence now permits us, at last, to answer these questions. The pathologists can now be seen in a new light, one that only minimally disparages their professional competence but one that exposes them to more sinister charges. Their behavior over the years is entirely consistent with this new view. In fact, my own prior perspective on them (Assassination Science 1998, pp. 104-107) has changed considerably over the past several years. I now believe that they were far more competent than has been supposed. The new evidence for this altered judgment is compelling. (As just one example of their competence, James J. Humes, the chief pathologist, admitted in a personal interview with Kathleen Cunningham ("The Plain Truth' and the Autopsy of John F. Kennedy," 1995) that he had supervised the weekly brain cutting conferences at Bethesda before the assassination.)

Missing Photographs

The evidence for missing photographs derives from a rather long list of witnesses, including Humes, Finck, Kamei (three physicians at the autopsy), Stringer, Riebe (two autopsy photographers), Knudsen, O'Donnell (two additional photographers), and Spencer (a darkroom technician). It is not merely that one, or even two, images are missing: a wide variety of views has simply disappeared, including whole body views, a close-up of the beveled wound in the skull, the interior views of the chest cavity, the bullet entry hole over the right eye, a view of the body with the brain lying beside it, views of probes passing through the body, as well as (probably several views of) the large hole at the right rear of the head.

Why is it important to know that photographs are missing? If true, then gaping holes are immediately opened in the entire case. What if the missing photographs showed an orange-sized hole at the right rear of the head, as so many witnesses have consistently recalled? In fact, since such a photograph currently exists in the official collection (as I demonstrate in

the Postscript), it is most likely that additional photographs once also showed such a large posterior hole. If such photographs once existed, then the conclusions of prior experts,

over multiple investigations, become immediately irrelevant. In view of this new evidence, the posterior photographs showing the red spot (which was taken to be the skull entry wound by the HSCA, and by almost all subsequent lone gunman supporters) now lie under the deepest suspicion.

Indeed, the HSCA's conclusion of a high, posterior, skull entry rested almost solely on these posterior head photographs, which never gained the full endorsement of any of the three autopsy pathologists or, for that matter, anyone else at the autopsy either. Even the two autopsy photographers (Stringer and Riebe) and the autopsy radiologist (John Ebersole) agree with the pathologists that this red spot was not an entry wound. Furthermore, even if these peculiar photographs (of the red spot) were authentic, they still could not tell us what is most important... i.e., whether the skull underlying the scalp was intact. Until that is certain, no serious conclusions can be drawn. Yet the HSCA ignored this simple guideline and chose to declare a conclusion anyway: namely that:

1. The red spot was the entry wound.
2. The skull bone at the back of the head was intact.

This is all quite simple: if photographs are missing and there can be scant doubt of this no, then no final conclusion can be drawn about the status of the right rear skull. That question must be answered by the X-rays (discussed in a separate section below) and by the eyewitnesses. These two clues to the puzzle are completely consistent with one another, and they indicate... convincingly that there was, indeed, a large hole at the right rear of the skull. Its variable appearance on 22 November 1963, however, proved to be a source of major confusion, as I have previously explained (Assassination Science 1998, pp. 331-332). Also see the notation "McC" (McClelland) in Figure 2C, which identifies the hinge on a posterior bone flap that occasioned much confusion. The recognition of this variable appearance of the posterior skull (depending on whether the flap was open or closed) permits this confusion finally to be laid to rest.

It might even be possible to believe in both an intact posterior scalp and a large hole in the occipital bone. Such a view strains credulity, however, in view of the major trauma to the posterior skull, as reported by so many witnesses and as actually seen on the X-rays. It might even be possible to accept the intact scalp as authentic and simultaneously to interpret the red

spot as a bloodspot (as Stringer suggested) or as an undefined artifact (as Dr. Humes suggested). But all of this reeks of sophistry to no useful end. That the photographic evidence was deliberately altered to mislead, in one- way or another, is inescapable.




Fig 2A The Harper Fragment[Exterior view] In the text this fragment is divided into three sections. (E) The left Parietal bone (F) The right Parietal bone (G) The Occipital bone

Figure 2A. The Harper Fragment (Exterior View) In the text, this fragment is divided into three sections: (E) the left parietal bone, (F) the right parietal bone (G) the occipital bone.




Figure 2B The Harper Fragment (Lateral view) Vascular markings and Foramina are consistent with both Parietal bone and high Occipital bone

Figure 2B. The Harper Fragment (Interior View) Vascular markings and foramina are consistent with both parietal bone and high occipital bone.

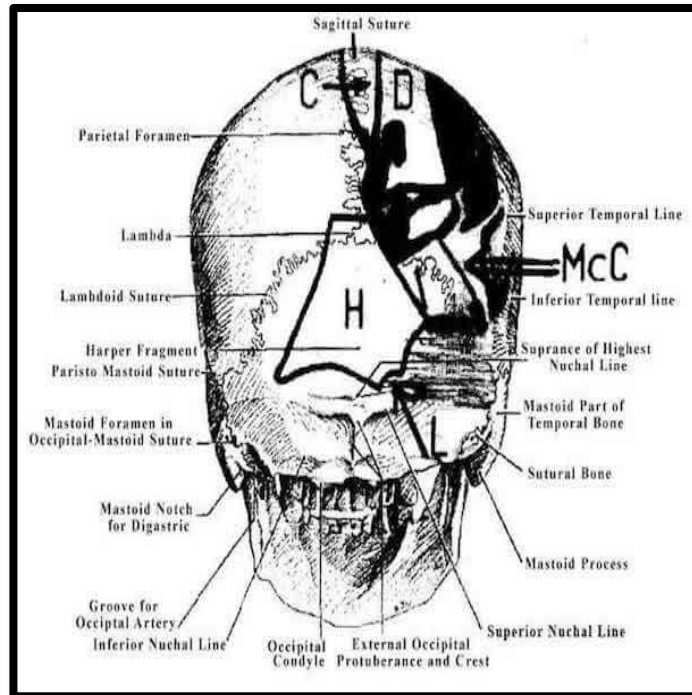


Figure 2C. As Situated in the Occiput H is the Harper fragment C and D are bone fragments seen on the skull X-ray and in Boswell's diagram. L is the site of lead on H. The 6.5 mm object is seen at about the 2 o'clock direction from the right upper edge of H. McC identifies the fracture line (which acted as a hinge) that McClelland described.

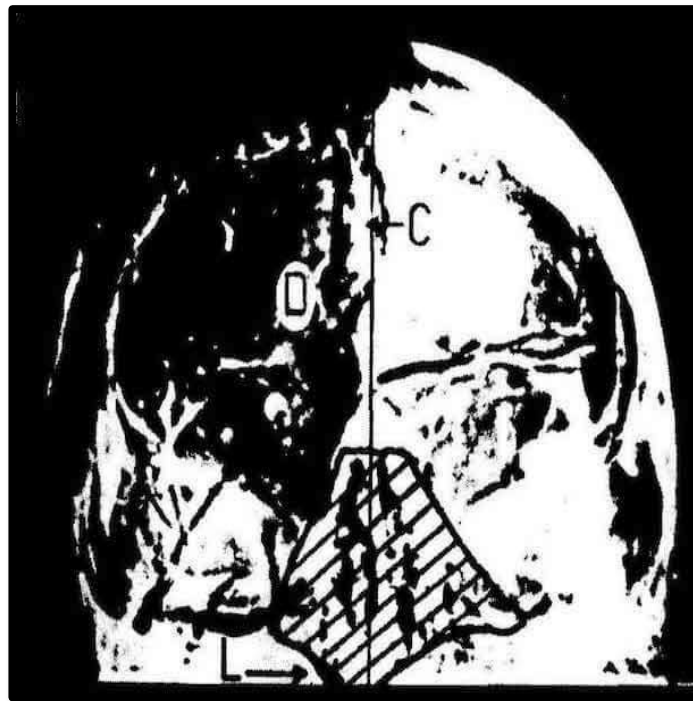


Figure 2D as Placed into the Frontal Skull X-ray, the lambda point (the junction of the two lambdoid sutures and the saggital suture) lies just inferior to the upper edge of the Harper fragment (H). L denotes lead on H. The EOP lies very near the inferior edge of the black border (at the bottom of the entire image)

For those who would argue that no photographs have been altered but instead that:

1. JFK's scalp has merely been photographed with a toupee (even though no one recalls such an event), or that:
2. The back of the head belongs to someone else; consider the following argument, which is based on Figure 3 (the back of the torso).

If the image of the scalp in Figure 1 did result from either (1) or (2), how then did JFK's (presumably authentic) back (of torso) become attached to the image of either (1) or (2) unless it was via photographic alteration? Or did the back of the torso also belong to someone else?

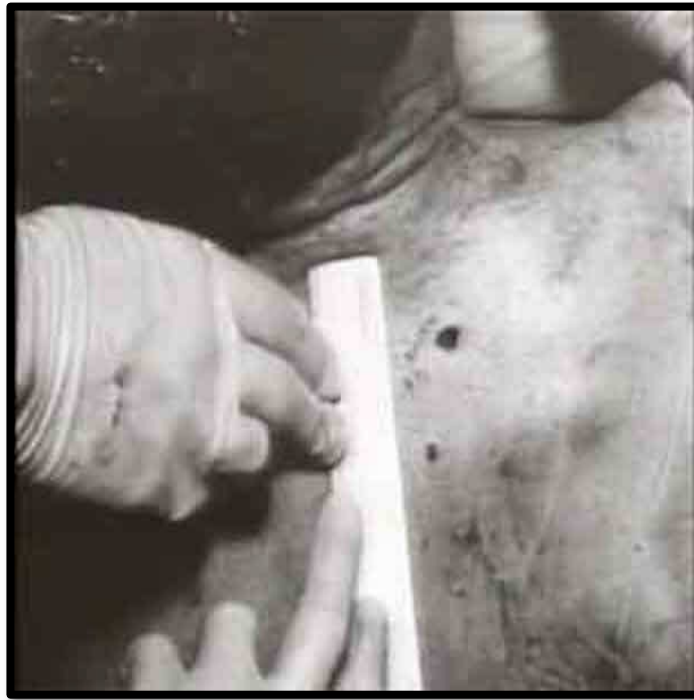

Figure 3. Official autopsy photograph of the back wound I would also ask which is simpler to believe:

1. That a few photographs were physically altered.
2. That no photographs were altered.

But rather that such a curiously odd set of posterior photographs naturally existed in the original set so as to lend them to the present deception? For option (2) to be viable, there had to be more than one photograph that fit such a deception, and these photographs had to be consistent with one another. When the statements of Knudsen, Kamei, Stringer, Riebe, Humes, Boswell, Finck, Spencer, and the autopsy technicians are taken into account, the first alternative appears inescapable. And when the nearly uniform statements of the Parkland Hospital personnel (who describe a large, right, posterior hole in the skull) are added to the equation, the case for photo tampering becomes virtually irrefutable.

Indeed, Spencer (the NPC darkroom technician) and Knudsen (the White House photographer) saw photographs that showed the large hole at the back of the head.

Moreover, James K. Fox (the Secret Service photographer) told Mark Crouch of a bum party (on approximately 6 or 7 December 1963) at which Robert Bouck (chief of the Protective Research Section of the Secret Service) deliberately destroyed photographs and X- rays (Harrison Livingstone, *High Treason* 2 1992, pp. 322-323). Even the

family of Robert Knudsen understood from Knudsen himself that such items had been destroyed. The simplest hypothesis is the one with the least clutter, although initially the most difficult psychologically is that of photographic alteration. ⁵ In the end, though, it is ultimately not essential that agreement be reached on the question of how the deception occurred. It is enough to know that the photographic evidence has been deliberately manipulated to mislead a deception that has radically altered the entire history of this case.

The Skull Wound

The official autopsy report affirms [Editor's note: This report appears in *Assassination Science* 1998, pp. 430-437]:

There is a large, irregular defect of the scalp and skull on the right involving chiefly the parietal bone but extending somewhat into the temporal and occipital regions. In this region there is an actual absence of scalp and bone producing a defect, which measures 13 cm in greatest diameter.

This distance of 13 cm is from front to back, as becomes apparent in Boswell's autopsy diagram (Figure 4A). Since the length of a typical skull is about 20 cm, this is truly an enormous hole, occupying well over one half its length. Furthermore, the word, "occipital," is actually employed here by Humes.

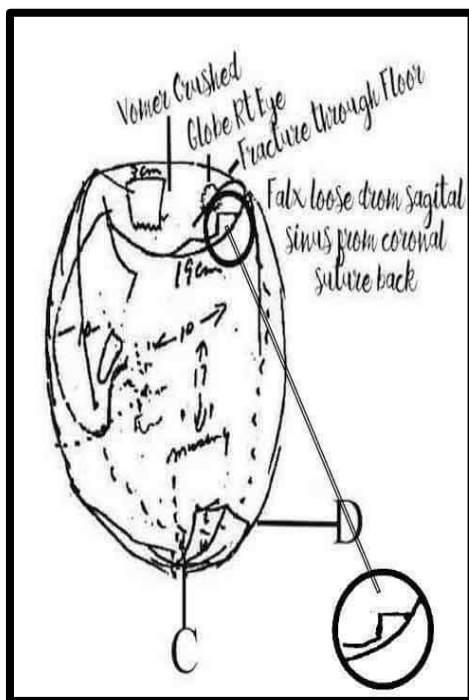


Figure 4A. Autopsy Diagram of the Skull by Boswell Letters C and D (added by the author) identify two bone fragments on the top-rear of the skull. Also see Figures 2C, 2D, and Appendix F.

The notch, discussed below, is circled.

The drawing (Figure 5) that Dr. Humes supervised in preparation for the Warren Commission (actually drawn by H.A. Rydberg, a Navy artist) is consistent with the above described size and location. The hole clearly extended into the occipital area. (For comparison, see standard skull anatomy in Figure 6.)

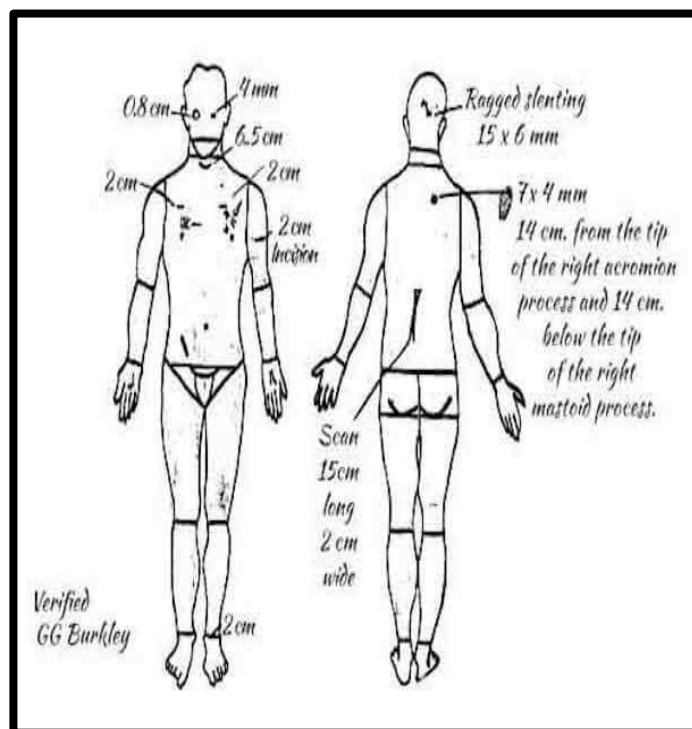


Figure 4B. Autopsy Diagram of the Back by Boswell After Gerald Ford elevated the back wound into the neck (to make the single bullet theory possible) Boswell agreed that he had placed the wound too low in this diagram.

The HSCA, however, shifted the wound out of the occipital area (thus nullifying three autopsy pathologists, two autopsy photographers, and the sole autopsy radiologist, as well as the medical personnel) into the parietal and frontal area (Figure 7) This large displacement was based primarily on the posterior head photographs, which showed intact scalp at the rear but also (the HSCA claimed) on the skull X-rays. With this translation from the back to the top of the head, the disagreement with virtually all of the eyewitnesses was complete, a strange incongruity that troubled even the HSCA.

The accuracy of the photographs, most especially those of the posterior head (Figure 1), seemed suspicious when they first became public in the 1970's. The fact that not a single eyewitness at either Parkland Hospital in Dallas or at the autopsy at the Bethesda National Naval Medical Center in Maryland described an entry wound high on the back of the head (the red spot in the color photographs) was quite arresting. In fact, virtually

every eyewitness described something quite different, not a small entry hole high on the back of the head, but rather a large (orange-sized) hole at the right rear of the head, much lower down, just above the hairline.

No such orange-sized hole is anywhere evident in the photographs. Instead, the scalp is entirely intact in this area and the hair is remarkably well groomed at exactly the same site where nearly all of the eyewitnesses recalled seeing a large hole. Such a groomed appearance is especially striking for someone who has been fatally shot in the head, whose head has literally exploded, and whose hair was not cleaned (as the questioned witnesses all agreed). The HSCA, however, hoped that it had buried this paradox:

Drs. Ebersole [the radiologist], Finck, and Boswell offered no explanation for the upper wound [the red spot], while Dr. Humes first suggested that it might represent an extension of a more anterior scalp laceration, incident to the exit wound, in spite of the fact that within the photograph the margins of the wound appear to be intact around the entire circumference. Dr. Finck believed strongly that the observations of the autopsy pathologists were more valid than those of individuals who might subsequently examine photographs. (7HSCA115). [Editor's note: This is page 115 of Volume 7 of the 12 HSCA evidence volumes.]

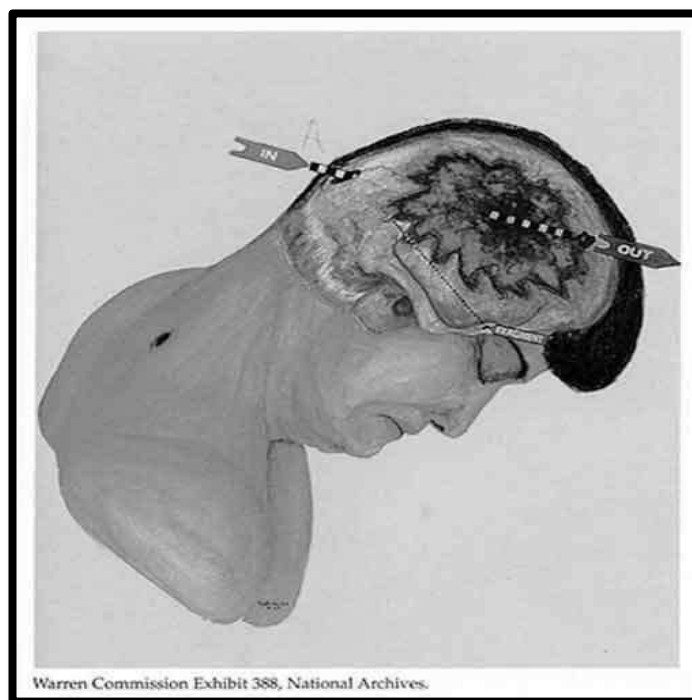


Figure 5. Rydberg (and Humes) Drawing of Skull Wound for the Warren Commission

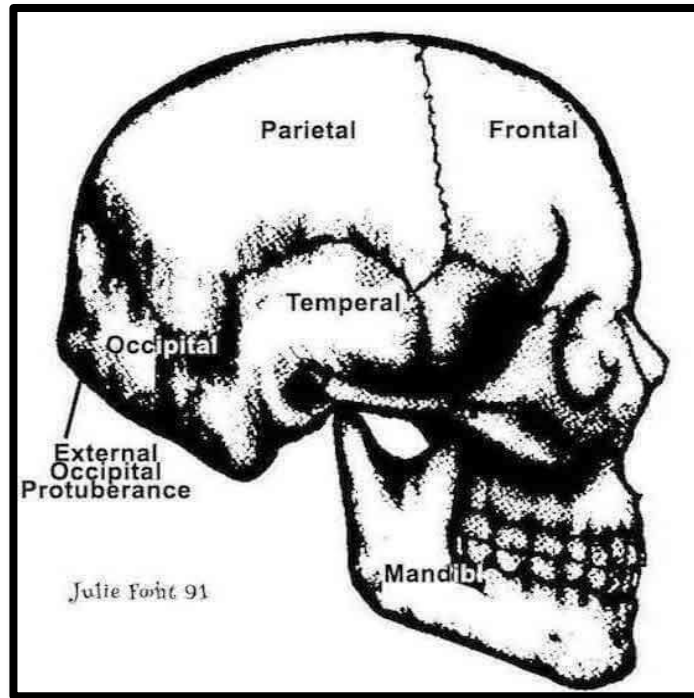


Figure 6. Normal skull anatomy illustration by Julie Foont, the Fundamentals of Operative Neurosurgery (1999)

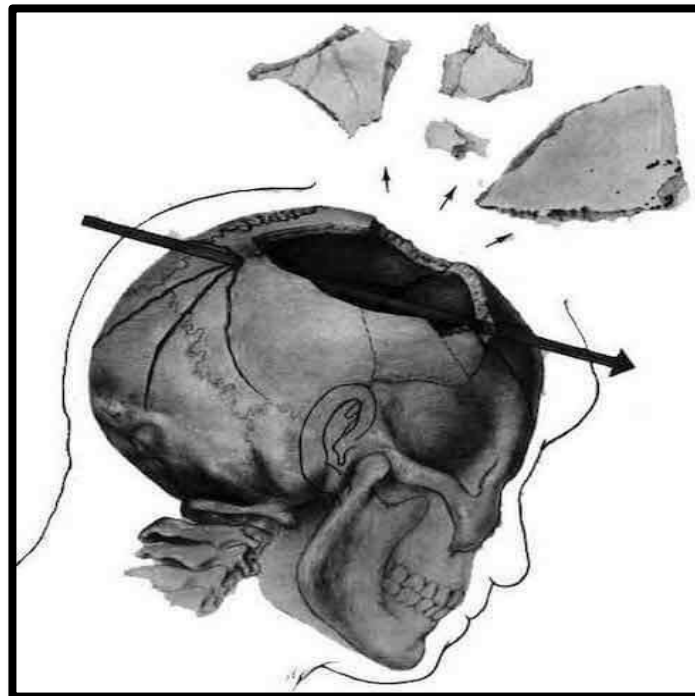


Figure 7. Skull Wound, as Interpreted by the HSCA. In disagreement with virtually every eyewitness, the HSCA moved the large hole from the back to the top of the head.

The panel continued to be concerned about the persistent disparity [of four inches] between its findings and those of the autopsy pathologists and the rigid tenacity with which the prosecutors maintained that the entrance wound was at or near the external occipital protuberance.

Subsequently, however, in his testimony before the select committee, Dr. Humes agreed that the defect was in fact in the "cowlick" area and not in the area of the brain tissue [just above the hairline]. [Author's note: Humes's indisputable admission vis-a-vis his bona fide opinion, is discussed further below.]

The HSCA concluded its findings on the large posterior hole in the skull as follows:

In disagreement with the observations of the Parkland doctors are the 26 people present at the autopsy. All of those interviewed who attended the autopsy corroborated the general location of the wounds as depicted in the photographs; none had differing accounts... it appears more probable that the observations of the Parkland doctors are incorrect (7HSCA 37-38).

Dr. Earl F. Rose was a member of the Forensic Pathology Panel. He had performed Oswald's autopsy, one that is widely recognized as a model, especially when compared to JFK's. Rose (7HSCA 115) the same page as the first quotation above) offered his opinion on another critical issue: the brain was not consistent with the wound described by the pathologists. In particular, the relatively intact inferior brain (Figure 8) would not have been expected, given the pathologists' low entry wound just above the hairline). On the contrary, the under surface of the brain should have suffered major trauma from a bullet that entered just above the hairline. This conclusion by Rose was eminently sensible and, at the time, seemed to provide strong support for the HSCA's much higher entry site. In retrospect, however, it is quite certain that Rose was viewing a substitute brain, not the brain of JFK. If true, his critique would be quite beside the point.

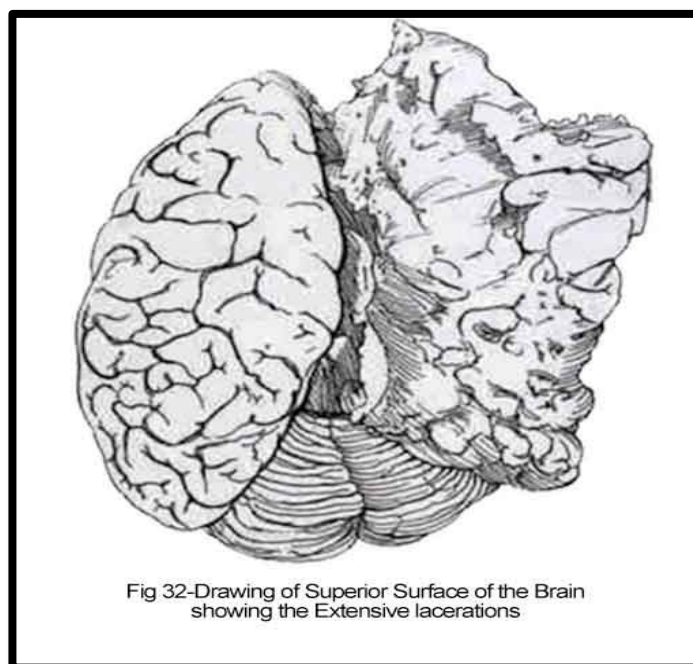


Figure 8. Drawing of the Brain by Ida Dox for the HSCA. Based on one of several photographs at the Archives, it almost certainly represents the substituted brain.

(For more details on the substitute brain, see my section on the two-brain proposal or the separate paper by Horne.)

The enduring paradox about the photographs (of the back of the head) led Harrison Livingstone in 1979 (just after the HSCA's final report) to do what both the Warren Commission and the HSCA should promptly have done. In

a trip paid for by Steve Parks of the Baltimore Sun (Robert Groden and Harrison Livingstone, *High Treason* 1980, p. 38), Livingstone traveled to Dallas and showed these images (actually copies of drawings of the back of the head, based on the work of the HSCA) for the first time to the Parkland medical witnesses. What he discovered was truly astonishing; the Parkland personnel radically disagreed with their authenticity. Livingstone reports:

Since then, Livingstone, *The Baltimore Sun*, and Ben Bradlee, Jr., of the *Boston Globe*, have compiled the testimony of a number of additional witnesses, and the startling conclusion of their work is clear: the autopsy pictures a re-fake, and hold the key to the true nature of the plot which took the life of the President. (The research conducted by the *Globe* and the *Sun* was subsequently turned over to Livingstone and placed in the JFK Library in Boston.) (Groden and Livingstone 1980, p. 38.) 6

For the 25th observance of the assassination (1988), four Parkland physicians (Robert McClelland, Richard Delaney, Paul Peters, and Marion Jenkins) traveled to the National Archives to view the autopsy materials. On leaving, they were asked by Nova if their recollections disagreed with the photographs. This time many investigators expected that they would disagree, but now another kind of surprise these physicians seemed to imply that they had seen no discrepancies. Nonetheless, on subsequent careful questioning, they later complained that the Nova program had either misquoted or misinterpreted their comments (Harrison Livingstone, *Killing the Truth* 1993, p. 305), meaning that the paradox was still alive. In particular, as Livingstone clarifies, all that these doctors had meant was that the pictures they saw in the Archives were the same as the pictures that had been publicly published.

The doctors had made no claim that the pictures accurately portrayed their recollections of 22 November 1963. Groden, subsequently, laid this matter conclusively to rest (Robert Groden, *The Killing of a President* 1993, pp. 86-88). He published photographs of these doctors, as well as similar photographs of other physician eyewitnesses and medical personnel, that show them clearly demonstrating (on their own heads) that the large hole was indeed at the right rear (and was usually quite low) in gross disparity with the photographs. 7 [Editor's note: A composite of the responses of these witnesses, based on Groden (1993), may be found elsewhere in this volume.]

The virtual uniformity of their demonstrations (with the notable exception of Marion Jenkins, who changed his opinion sometime after 1978) was remarkably compelling. The paradox between the witnesses and the photographs therefore still persisted. Moreover, those physicians who had entered the National Archives had not been queried about the obvious "entry" wound in the photographs (the red spot). In fact, in their detailed medical notes of 22 November 1963, none of these doctors had mentioned such a small entry site, a truly astonishing oversight, if indeed, this "entry" site had existed at all that day.

Even Jeremy Gunn (by then an ex-executive Director for the ARRB), commented during his deposition of five Parkland doctors on 27 August 1998, in Dallas, Texas: "In my very lay sense... and I am not a doctor

...there seems to be a fair degree of coherence among the testimony that you offered about the (rearward) location of the (skull) wound." Moreover, now that the ARRB has concluded its work, we know that the witnesses still disagree-and disagree dramatically with the photographs. Due to the efforts of Gary L. Aguilar, M.D., we now know what happened to the missing interviews with the Bethesda witnesses: they were sequestered until the year 2029.

After these interviews (and wound diagrams by the witnesses) were finally released in 1993 by the National Archives. Aguilar reviewed them, and was forced to an amazing conclusion: the HSCA's summary statement was patently wrong. In fact, essentially all of these Bethesda witnesses agreed that there had been a large hole low on the right rear of the skull. In 1995, Aguilar presented this startling discrepancy at a Washington, D.C., conference whose audience included Michael Baden, M.D., Chairman of the HSCA Forensic Pathology Panel and Andy Purdy, an HSCA staff member (for the medical evidence). I was also present. During this historic denouement, Baden denied any knowledge of this fundamental conflict, and Purdy denied writing the misleading conclusion.

So what had gone wrong? Although no one has yet acknowledged this egregious error ...Dr. deliberate deception... after 1 January 1979, only three individuals could have written this misleading HSCA conclusion. They were the only three staff members left: Robert Blakey, the Chief Counsel; Gary Cornwell, Deputy Chief Counsel; and Richard Billings, who had been hired to assist with the writing of the report. ⁸ When Aguilar queried each of them about this gross inconsistency on an absolutely pivotal facet of the case, each of these principals denied writing this statement. Seeking final

confirmation on this crucial issue, I sent each of them certified letters (receiving appropriate receipts in each case), with the following responses:

1. G. Robert Blakey-no reply;
2. Gary Cornwell-no reply;
3. Richard N. Billings-no reply ⁹

Two unlikely authors... since they both left the HSCA before 1 January 1979 are Andy Purdy and Mark Flanagan, who both worked with the medical witnesses. When Aguilar wrote to inquire of Flanagan, he never replied, while Andy Purdy not only denied writing the misleading summary, but also added that he was quite displeased with the misleading summary. To date, he is the only HSCA staff member to express such displeasure. This remarkable (and all too convenient) loss of memory by the probable participants, particularly on a matter of such central importance... duly raises questions about the integrity (or the sincerity, or the competence) of those involved.

The pathologists themselves, although not openly describing these photographs as forgeries, have nonetheless been at some pains to intimate that something was very

wrong. When asked about this flagrant "entry" wound (the red spot) high on the back of the head, Humes put the Forensic Pathology Panel on notice:

I can assure you that as we reflected the scalp to get to this point, there was no defect corresponding to this [red spot] in the skull at any point. I don't know what that [red spot] is. It could be to me clotted blood. I don't, I just don't know what it is, but is certainly was not a wound of entrance (7HSCA 254).

Without actually labeling these photographs as forgeries, Humes could go no further without exposing the entire affair.

Pierre Finck, the third pathologist (on loan from the AFIP), when questioned by the HSCA in 1978, was somewhat more forthcoming. What was particularly striking was that:

1. He specifically requested one more day with his questioners to review the photographs.
2. His testimony, like so many others, had been sealed until the year 2029.

This latter decision of what to seal and what to release could only have been made after 1 January 1979 by the skeleton three people HSCA staff led by Chief Counsel Robert Blakey. (The records were sequestered for 50 years, as was typical for such Congressional investigations: 1979 +50= 2029.)

Finck said that he did not know what either the white or the red spot were, but that the actual wound was much closer to the white spot (seen very near the hairline in Figure 1). At the autopsy, the pathologists had identified this wound by both:

1. A perforating wound in the scalp.
2. A matching beveled entry site on the skull.

Since Finck had previously stated that the skull entry site showed only a portion of a crater (i.e., it was not completely circumferential), the implication was obvious: bone near this site was missing (independent of the scalp's photographic appearance). By implication, based on Finck's testimony, the photograph that had played such a critical role for the HSCA was worse than useless: it not only failed to portray the actual entry hole but, even worse, it showed an entry hole that was wrong.

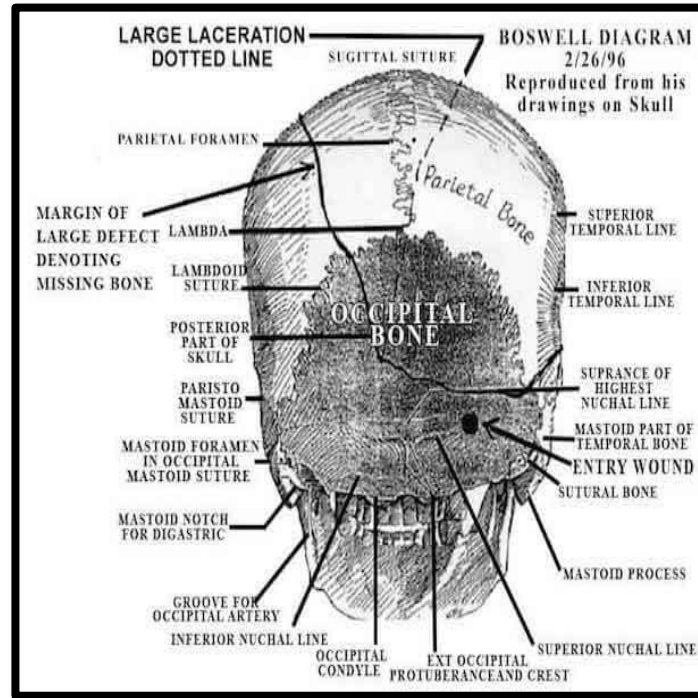


Figure 9A. Horne's rendition of Boswell's drawing of the back of the skull (#1 of 4).

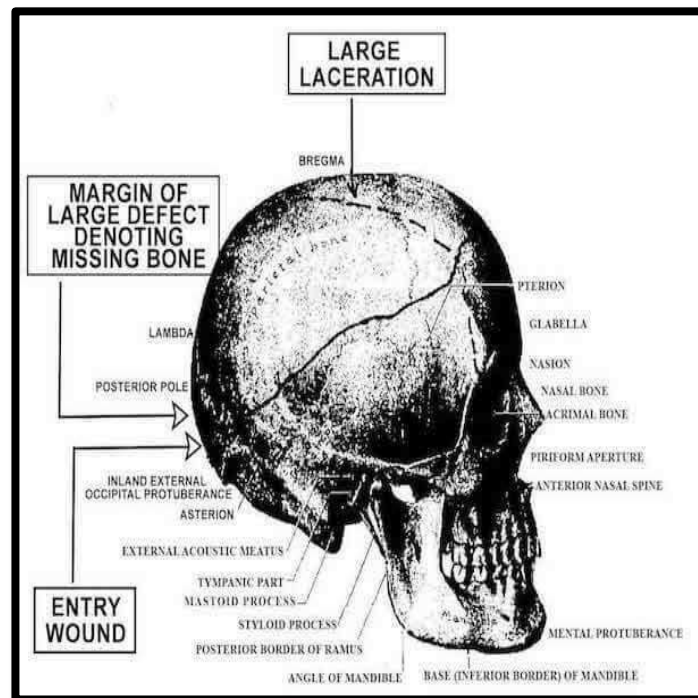


Figure 9B. Horne's rendition of Boswell's drawing of the side of the skull (#2 of 4).

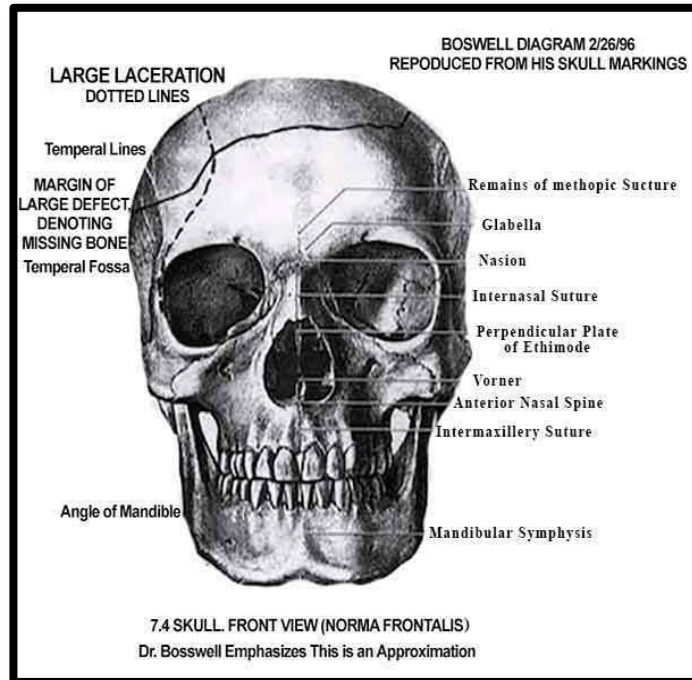


Figure 9C. Horne's rendition of Boswell's drawing of the front of the skull (#3 of 4).

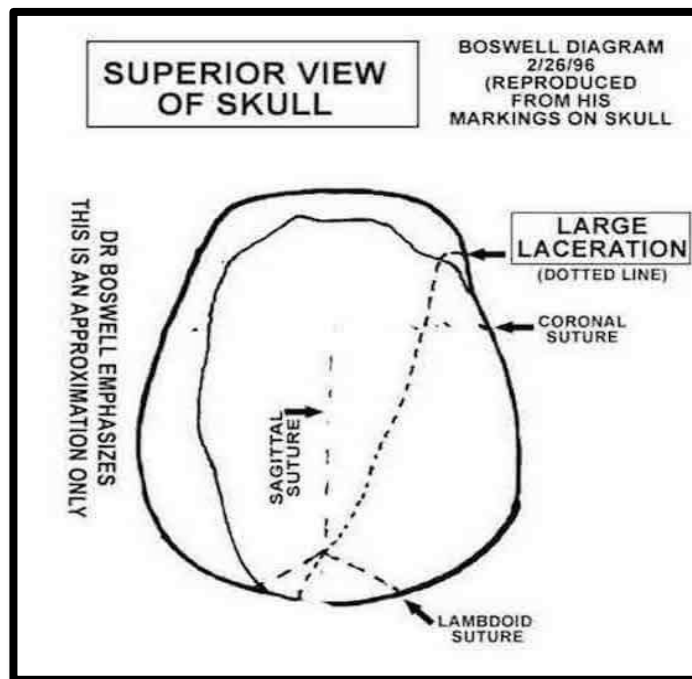


Figure 9D. Horne's rendition of Boswell's drawing of the front of the skull (#4 of 4).

Only one diagram remains from the autopsy itself: a crude sketch made by Boswell (Figure 4A) that shows a huge bone deficit, as described above (13 cm). Such a large size, by itself, would require that the large hole extend into the occipital area. In fact, Boswell clarified this for the ARRB by actually drawing this large hole on a skull. (Figure 9 is Horne's 2D reproduction of Boswell's drawing on a 3D skull.) In this sketch, a large hole does in fact extend far into the occiput, well into the region where the scalp appears to be intact in the photograph.

Although Humes, in his ARRB testimony, stated, for the very first time, that the occipital bone was intact under the scalp, saying that the entry hole was completely circumferential, that is not at all what he had stated previously. In fact, like both Boswell and Finck, he had previously reported that the entry wound was only partially circumferential, meaning that some bone was necessarily missing under the visible scalp in the famous photograph. By telling this unexpectedly new story to the ARRB, Humes contradicted both:

1. His own Warren Commission diagram.
2. Also the actual word "occipital" in the official autopsy report that he himself had written.

In summary, then, none of the three pathologists could explain:

- (1) Why the scalp (at the right rear) appeared so intact in the photograph (despite the absence of cleaning on, which they agreed)
- (2) What the red spot represented.
- (3) What the white spot represented.
- (4) Why the supposed entry site was not centered in the photograph.

In fact, in view of all of these points the photographs (of the back of the head) actually served no purpose at all. Worse than that, though, these photographs were misleading, and showed an "entry wound" that no one could recall. Although Boswell did not recall the red spot, nor could he see (in the photograph) the actual entry wound, when asked by the ARRB if the photograph had been altered, he evaded the question. Instead, he merely suggested that, on technical grounds, he doubted that a photograph could be so altered. The primary question of whether the photographs actually looked altered... remained forever unanswered. This question was not put to Humes. [Editor's note: See the diagram of different descriptions of the head wound-at Parkland, at Bethesda, and by the HSCA, elsewhere in this volume.]

The three pathologists were hardly alone in their skeptical opinions of these (back of the head) photographs. When John T. Stringer, the chief autopsy photographer, was deposed, he also agreed that the entry site had been low on the back of the head and that it was not the red spot in the photographs. I personally interviewed the one autopsy physician, John Ebersole, in my own specialty (radiation oncology). He, too, concurred with the low entry site. In fact, it is quite striking that no one at the autopsy (or at Parkland, either, for that matter) ever recalled the red spot. It was this site on which the HSCA and all subsequent, lone assassin advocates have established their case. This point is so critical that it needs to be restated: the most critical piece of evidence for the HSCA's case, the red spot was never reported by any witness, at either Parkland or at Bethesda. The HSCA literally based its case on a piece of paper.

In view of the HSCA's misleading summary statement (7HSCA37-38, cited above), this now known consistency between the Parkland and the Bethesda witnesses (that there had been a large hole at the right rear) was quite unanticipated. Aguilar then displayed these (approximately 40) witness statements in a remarkable table (see Aguilar's article). Of these, all but one witness agreed that there had been a large hole at the right

rear of the skull. (The one exception recalled a similar wound, but on the left side.) Faced with this astounding near unanimity between Dallas and Bethesda, advocates of authenticity (of the posterior head photographs) now had only one 'recourse, and they repeated it almost as a mystic incantation, eyewitnesses are not reliable! Of course, even these devotees could say nothing at all about the status of the posterior skull, which was; after all, the primary issue, the problem was that the scalp covered the area of the skull in question. The proper conclusion of the HSCA regarding the status of the skull should have been agnosticism, but they willingly crossed this line.

To this now hoary myth of eyewitness unreliability, the work of Marshall, et al., has given us a wholly new perspective. The eyewitness evidence from this study is presented in detail elsewhere. [Editor's note: See Dr. Mantik's essay on the Zapruder film in Part V.] Although eyewitnesses may be unreliable when asked to recall (especially much later, as in criminal trials) specific details of a complex sequence of events, or the exact features of a stranger's face only briefly glimpsed (such as those witnesses who thought they saw Oswald on November 22), under the right circumstances they can be remarkably accurate. These requirements are straightforward: the events in question must be simple and salient, and the events must be promptly recalled. When these conditions are met, eyewitnesses are often 90% accurate, and sometimes even 98% accurate, as the Marshall study showed. And when many witnesses independently recall such an event in just the same way, such as a hole in the back of the head, then the final conclusion is as certain as most events in life can be.

As Aguilar has often emphasized in his public presentations, if these witnesses had made merely random errors of recall, then the entries in his table should be randomly scattered between the two columns. Obviously, they are not the witnesses are in remarkable agreement that there was a large hole at the right rear of the head (and that it was closer to the bottom than to the top of the head). When it is further recalled that many of these witnesses were trained professionals, physicians accustomed to seeing daily trauma in the ER (including the chief of neurosurgery whose observations of the brain were critical to resuscitation efforts), and that they all recalled the posterior head in the same way, the evidence for such a large hole begins to seem incontrovertible. It surely cannot be argued that this large hole was not both simple and salient. Furthermore, the contemporaneous notes of the Parkland physicians were published in The Warren Report, and are still easily obtainable at most local bookstores and libraries. Their depictions in these notes are undeniable. [Editor's note:

Curiously, many of these published notes were handwritten, making them difficult to read, which may now be understandable. See The Warren Report 1964, pp. 485-491.]

Those who argue that these photographs of the scalp accurately portray the posterior skull (two clearly different anatomic areas, for which two different sets of data are required) have necessarily insisted that the physicians, since they were primarily trying to save a life, were too hurried to make accurate observations. However, both Drs. Giesecke and McClelland give the lie to this version they recall using a flashlight to peer inside the skull for some time. McClelland described the back of the head in some detail:

As I took the position at the head of the table... I was in such a position that I could very closely examine the head wound, and I noted that the right posterior portion of the skull had been blasted. It had been shattered, apparently, by the force of the shot so that the parietal bone was protruded up through the scalp and seemed to be fractured almost along its posterior half, as well as some of the occipital bone being fractured in its lateral half, and this sprung open the bones that I mentioned in such a way that you could actually look down into the skull cavity itself, and see that probably a third or so, at least, of the brain tissue, posterior cerebral tissue and some of the cerebellar tissue had been blasted out (6H33). [Editor's note: This is page 33 of Volume 6 of the 26 volumes of the Warren Commission Hearings.]

McClelland's description is remarkably consistent with the X-rays, as I explain below. It also explains why the Zapruder film shows no obvious hole in the back of the head after the final headshot (traditionally, at about frame 313), which I have previously discussed (Assassination Science 1998, pp. 263-342).

On another occasion, after noting that one-third of the brain had been blasted out, McClelland added the following comments:

...There was not only a horrible gaping wound but that it was (sic) a cavity that extended down into the head. And as I stood there holding the retractor, I was looking down into it all the time. I was no more than eighteen inches away from the wound all the time, standing just above it, 'which was ten to fifteen minutes at the least. And during that time I had a continuing impression of that gaping cavity. And during that time I had a strong impression that a portion of what appeared to be the cerebellum fell backward through the wound onto the scalp and hair that was hanging back from the head... There was a great deal of matted hair and blood around the edges of [the wound]. ...At the National Archives [for the Nova show] it was my assumption, and it was just an assumption that there was enough of the flap left to pull up over the back portion of the wound and to hide the ...wound ...One might be led to believe that this was intact head back here. That's not the case. It wasn't. The skull was missing underneath the scalp (Livingstone 1992, pp. 288-289.).

When the ARRB interviewed (21 March 1997) a second neurosurgeon, Dr. Robert G. Grossman, who had assisted at in Trauma Room One, he also recalled that he and Kemp Clark (chief of neurosurgery) had to lift the head in order to see the large hole, which clearly implied that it was not at the top of the head where the HSCA had placed it. His more detailed anatomic description confirmed a low right posterior hole in the skull, so low that the cerebellum could be seen.

These photographs (of the back of the head) are, at the very least, not an accurate portrayal of the real condition of the head. Several witnesses: Riebe, O'Neill, Kenneth Salyer, M.D., Fouad Bashour, M.D., Jackie Hansen Hunt, M.D., as well as several Bethesda medical personnel have either disagreed forcefully with the official photographs or have overtly charged photographic alteration.

This section is appropriately closed with a list of physicians who, at some time, stated that the photograph of the back of the head was (at least) distinctly different from what they had seen at Parkland:

Kemp Clark Marion Jenkins Joe Goldstrich Jim Carrico Gene Akin Paul Peters

Richard Delaney Fouad Bashour Jackie Hunt Ronald Jones Charles Baxter Kenneth Salyer Malcolm Perry Robert McClelland

Charles Crenshaw Adolph Giesecke.

In case the reader is waiting for a companion list, those who saw this photograph and immediately recognized it as authentic, there is none. No Parkland physician, on first seeing the posterior photograph of the skull, recognized that image as authentic!

The Autopsy Photographs

If these eyewitnesses to the state of JFK's skull are correct, how then are these photographs to be explained? It is here that the ARRB's new evidence is particularly arresting. The ARRB discovered witnesses previously unknown to the public who provide remarkable substantiation, each in his or her own way (and with no apparent personal agendas), for either highly misleading photographs or possibly even for photographic alteration. Although they suggest no reasons for such alteration, their evidence, when taken collectively, is unprecedented in the annals of forensic science.

Sandra Spencer, NPC photo technician

Sandra Spencer, a photographic technician who worked at the secretive Naval Photographic Center (NPC) in Anacostia, Maryland, recalled, under oath, that she had processed and handled JFK autopsy films. 10 A Secret Service agent, whom she thought was James K. Fox, had brought to her about four or five duplex film holders (containing eight to ten individual films) for processing, probably on Sunday morning, November 24. It is critical to note that these were color negatives, not transparencies. She is sure of this because her division did not handle color transparencies.

Three features immediately leap out as anomalous in her account:

1. The use of Anacostia, when Bethesda had its own photo lab and where autopsy photographers always did their own processing...
2. The rather limited number of films (far too few to represent the entire autopsy) ...
3. The presence of color negatives, rather than color transparencies.

According to Stringer, the autopsy photographer, the only color photographs exposed were color transparencies, not color negatives. Furthermore, only color transparencies exist in the Archives today, there are no color negatives.

What Spencer added next was even more striking. She had retained, and brought with her to the deposition, a photograph of JFK that had been developed about ten days before the assassination. It had been taken at an event that she was able to identify and to date. By comparing the identifying marks on this film to the autopsy films, she was able to conclude that she had developed none of the extant autopsy films. In addition, after reviewing the autopsy films, she stated that none of the images were like those she had developed and printed. (She had printed at least one view of the face, so she was sure that it was JFK.)

She recalled that the images she had seen in 1963 were clean and free of blood, not at all like other autopsies she had seen. This blood-free characteristic is similar to the

extant posterior head photographs (Figure 1) but not like the blood-spattered untidiness that virtually all of the eyewitnesses have recalled. There were no measuring devices, as she would ordinarily have expected, and no identification tags. She saw a small throat wound, about the diameter of thumb or a finger, about half an inch across, by her description (much smaller than that seen in the extant autopsy photographs). Most important of all, however, she saw a photograph of the back of the head with a 2 or 2½-inch hole just about where all of the eyewitnesses placed it.

Robert Knudsen, White House photographer

Robert Knudsen was deposed by the HSCA, but, since he died in 1989, he could not be deposed by the ARRB. For the HSCA, he recalled seeing photographs with multiple probes in the body, showing the points of entry and exit, with the point in the back lower than the point in the front, an obvious violation of the single bullet theory (SBT). Knudsen was one of several witnesses who recalled probes in the body (including several witnesses who saw them in photographs). Such probes were also described in a CBS memorandum (10 January 1967) from Robert Richter to Les Midgley, [11](#) in which a conversation with Humes himself was recalled by Jim Snyder of the CBS bureau in Washington, D.C. Snyder went to the same church as Humes, but also knew Humes's boss, who lived right across the street from Snyder. Humes implied that one X-ray, apparently with a probe in it, would answer many questions about the [supposed] bullet trajectory from the back to the throat.

The Knudsen family added further, astonishing details when interviewed by the ARRB. Mr. Knudsen had told his wife that the Secret Service had destroyed autopsy films. He had also told her that he knew who was probably responsible for the disappearance of some of the autopsy films, but that he was not going to stick his neck out because he had a family to protect. [12](#) Secret Service agent, James K. Fox, had also told Mark Crouch a similar story about destruction of autopsy photographs and X-rays (Livingstone 1992, p. 245). Mrs. Knudsen telephoned a former Navy colleague who recalled one photograph that showed the back of the head "blown out." On follow-up, she confirmed that this was indeed the back (not the top) of the head.

Shortly after her husband had testified to the HSCA, moreover, there had been a burglary of her own house; she still wondered if there was a connection. All available family members agreed that Mr. Knudsen had photographed the autopsy and that it was the hardest thing he had ever had to do. Furthermore, he had told them that he was the only one in the morgue with a camera. (Paradoxically, however, no one actually in the morgue recalls his presence.) All three interviewed family members did not see him at home for three days after he left to meet Air Force One at Andrews Air Force Base.

After his HSCA appearance, he told his family that four or five pictures that he was shown were not consistent with the autopsy, and that one of the photographs had been altered. His son, Bob, said, "hair had been drawn in," on one photograph to conceal a missing portion of the top-back of the head.

All three family members agreed that Mr. Knudsen had appeared before an official government body in 1988, about six months before he died in January 1989. They all believed that he had testified on Capitol Hill, and that it may have been a

Congressional inquiry. All were unanimous that he had returned from this encounter feeling very disturbed, saying that four photographs were missing and one was badly altered. Mrs. Knudsen actually used the phrase, "severely altered," several times. She confirmed that the photographs he saw in 1988 were not consistent with what he had seen at the autopsy. He had also added that the details in the background of the room were wrong (the autopsy medical personnel agree with this). He concluded that this encounter had been a waste of time, because as soon as he would answer a question he would immediately be challenged and contradicted by those who had already reached their own (different) conclusions.

Joe O'Donnell, USIA photographer

Joe O'Donnell, friend and occasional colleague of Robert Knudsen, was deposed by the ARRB. Within a short time after the assassination, in fact on two different occasions, Knudsen had shown him autopsy photographs. On the first of these, he saw a hole (about the size of a grapefruit) in the back of the head, about two inches above the hairline. This hole penetrated the skull and was very deep. Another photograph showed a hole in the forehead, above the right eye; this wound was round and about 3/8 inch in diameter.

On the second occasion the back of the head photograph was intact, and the hair was neatly combed, looking slightly damp or wet (reminiscent of Figure 1). On this second occasion, the wound over the right eye had disappeared. He also recalled an image of JFK lying on his back, with a metal probe emerging from his right side (no probes are visible in the current collection).

During a second interview, he again recalled a gaping wound at the right rear of the head, big enough to put his fist through; there was a total absence of hair and bone. He repeated that there was an apparent entry hole above the right eye, which he interpreted as the bullet that had caused the large hole at the right rear of the head. (This photograph no longer exists.)

He also recalled showing the Zapruder film to Jackie Kennedy, who said that she never wanted to see it again. O'Donnell interpreted this to mean that he was to remove the headshot images, so he took out about ten feet! He believes that this was the original film. The reason he is certain that this was the original film (I listened to this repeatedly on the audiotape) is that the Zapruder film that he has since seen (on multiple occasions on television) is quite unlike the one that he saw. He specifically mentioned a very obvious halo around JFK's head after a headshot that he no longer sees on the current film. 13

Robert Karnei, M.D.

Karnei, pathology resident at Bethesda (and later chief at the AFIP), would have performed the autopsy had it been a routine one. He recalls repeated attempts by Finck to probe the wound in the right shoulder. One of his certain memories is that photographs were taken of the probe in the wound (no such photograph exists). He recalled that Humes twice had asked for permission to enlarge the scope of the autopsy, first for the chest, then later for the abdomen. (Humes has adamantly claimed that he was solely in charge.) Karnei said that the control at the autopsy was so tight that he was

surprised that the pathologists were allowed to take their notes out of the morgue. (Finck never did find his... see Aguilar's essay.) He recalled that the embalmers were putting some wax into a tear or a laceration near the eye. (This may be corroboration for a shot to the right temple/forehead. An embalmer, Tom Robinson, has also recalled his work at this site; his recollections are introduced later.) Karnei had heard a story that Dr. Humes had called Dallas to talk to a surgeon later in the evening, before the body left the morgue, from which they had learned that the tracheotomy had been made through a bullet wound in the throat. (The pathologists, especially Humes, have claimed that they were entirely ignorant of this wound until the following day, Saturday, 23 November.)

John Stringer, the Photographer

Stringer admitted that, contrary to his usual practice, most photographs taken on 22 November 1963 had no identification cards. He had used a large format, Graphic View camera, which required duplex film holders. He listened to a tape recording he had made with David Lifton in 1972, in which he located the large head wound at the rear. With the ARRB, however, he claimed that the back of the head photograph was authentic and that his earlier recording with Lifton was wrong. Despite using the word "occiput" in the Lifton interview, he was now unable to explain why he had used that word!

Despite seeing no new physical evidence, he had changed his mind about the location of the large hole. After seeing the posterior photograph, he no longer believed that the large hole was at the back of the head. Nonetheless, he did not accept the red spot as an entry hole, claiming instead that it was an insignificant blood clot. Although he saw, in the photograph, that the scalp was entirely intact, he nonetheless insisted that the bone beneath it was disrupted, but he was uncertain about whether all of the occipital bone was present.

He recalled taking photographs of the skull interior, which he no longer saw in the collection. Most importantly, however, he recalled photographing the brain and brain sections. None of these photographs exist today, as he was able to prove by examining the type of film used for the extant photographs; the film he had used was a different type.

When asked about the document that he had signed (which said that all of the photographs were present), he said that he knew the document was false, but that he had been ordered to sign it. He agreed with the pathologists about the location of the entry hole, which was near the white spot. He concluded by saying that a shot from above and behind would not fit with the wounds he saw, which was in obvious contradiction to the SBT.

John W. Sibert, FBI note taker

Sibert recalled for the ARRB that the massive skull wound was at rear and that the hair was all matted, blood-soaked, and stuck together. The wound in the back as well below the shoulders... even below the scapula... The largest metal fragment in the skull was behind the right frontal sinus (not at the back of the skull, where the 6.5 mm object is located today on the skull X-rays). Like O'Neill, he still recalled that Humes had described surgery to the head (consistent with Lifton's thesis that the body had been

altered). Furthermore, he recalled that Humes had never retracted that statement at the autopsy. He recalled a chrome probe placed into the back wound. Very near the end of the autopsy, Humes had concluded that the back bullet had fallen out during cardiac resuscitation. Like virtually everyone else who was asked, he did not recall the stirrup under JFK's head. Most importantly, the photograph of the back of the head did not look at all like what he saw at the autopsy. He even questioned whether the skull had been reconstructed (no one at the autopsy saw any reconstruction). On the contrary, just where the scalp is entirely intact in the photograph, he had seen a large wound at the autopsy. Like O'Neill, he disputed many significant points in Specter's statement to the Warren Commission (related to their own FBI report about the autopsy). He concluded by admitting that he was unsure about conspiracy, but that he was certain about one thing, the SBT could not possibly be true, because he saw exactly how low the back wound had been.

Francis X. O'Neill, FBI note taker

During the evening of the assassination, O'Neill interviewed Roy Kellerman (who had occupied the right front seat of the limousine). Kellerman was certain that he heard JFK speak after the first shot, meaning that the bullet could not have passed through his throat. (This would invalidate the SBT, since that bullet would have rendered JFK speechless.) He severely criticized Specter for ignoring this part of his report (which is understandable since Specter wanted no contradictions to his SBT). He regarded Specter as a flunky for the Warren Commission. He was extremely surprised that the Warren Commission had interviewed neither him nor Sibert. Furthermore, their FBI report of the autopsy had been left out of both The Warren Report as well as the 26 volumes of the Hearings. He also recalled that the back wound was at least two inches down from the shoulder.

He recalled that much of the brain was missing, definitely inconsistent with the brain images in the Archives, which he was shown. His best estimate was that more than one half of the brain was missing. As further confirmation of this, he recalled seeing a great deal of brain tissue on the jackets of Kellerman and Greer. [Authors note: The extant brain photographs, which I have seen on multiple visits, show rather little brain tissue missing.] He recalled looking at the X-rays as long as the pathologists did, and he did not recall the 6.5 mm object. Perhaps even more importantly, however, he did not recall any discussion of such an object at the autopsy.

He severely disagreed with Boswell's upward relocation of the back wound in 1977; in fact, he ridiculed Boswell for changing this location. [Authors note: Boswell had disagreed with his own autopsy diagram! He had probably been enticed to do so in order to support the SBT, which was de rigueur by then.] He recalled that the brain was weighed! [Authors note: The pathologists have never actually denied this; they have simply claimed not to know why the weight was missing from the record.] Like everyone else who was asked, he did not recall the stirrup under the head either. He remarked that the eyes were open at the autopsy, but in the photographs the appearance of the eyes was not consistent. At one point, he described the back of the head photographs as "doctored," although later he seemed to want to retract this. In any

case, the photographs looked nothing like the head at the autopsy. He specifically did not recall the hair as being so clean.

Weighing the Evidence

If this case were straightforward, none of these recollections should exist. By themselves, these accounts of Spencer, Knudsen (and his family), O'Donnell, Karnei, Stringer, Sibert, and O'Neill provide striking evidence for photographic alteration. However, the narrative does not end there. In view of the now conspicuous agreement between witnesses at Parkland and Bethesda (that there was a large occipital hole) and the relentless disagreement of the pathologists with the HSCA (about the level of the rear entry wound in the head), the testimony (many under oath) of these newly found witnesses greatly increases the probability of photographic alteration and calls into question the accuracy of the extant photographs (of the back of the head).

Since these photographs do not accurately portray the wounds, that, by 'itself, is quite enough to severely challenge the conclusions of prior investigations. The extant autopsy photographs have been described... even within the ARRB as doing more to conceal than to reveal the actual nature of the skull wounds. Moreover, because the pathologists have repeatedly insisted that they carefully documented all of the critical features with photographs (they had stated to JAMA [14](#) that these wounds were obvious), the conclusion is inescapable, the photographic collection has been deliberately manipulated to mislead.

The presence of a left lateral skull photograph, and the simultaneous absence of the potentially much more pertinent right lateral, suggests deliberate culling of the collection. Furthermore, Earl McDonald, an autopsy photographer trained by Stringer, described how photographs were usually taken with stepwise closer views and with thorough labeling. This was, in fact, Stringer's usual practice, according to McDonald, but none of these features are seen in the present collection. Suspicions are only aroused when it is recalled that Stringer was known to be a very meticulous and widely respected photographer.

If the photographs had shown the true state of JFK's head, according to the witnesses who saw such photographs of a large hole (to say nothing of the many witnesses who saw the actual hole), it is highly unlikely that the HSCA would have concluded that the fatal shot had come from the rear. In fact, the exact opposite is far more likely faced with such a large hole in the back of the head and with no apparent entry site for a posterior bullet, they would have concluded that JFK had been shot from the front. In view of the statements of far too many witnesses, Humes, Boswell, Karnei, Stringer, Riebe, Knudsen, O'Donnell, and Spencer, critical photographs are indeed missing. Furthermore, Sandra Spencer, Robert Knudsen, and Joe O'Donnell specifically recalled seeing and handling photographs that did show a large hole at the rear.

Not a single eyewitness at either Parkland or at Bethesda (certainly not the pathologists) has endorsed the red spot as an "entry" site, surely a unique state of affairs. How is it possible for literally no one to have seen an entry site that Humes (according to JAMA) found "blatantly" obvious? On the contrary, the fact that the true entry wound is not visible at all strongly suggests that something is profoundly wrong with this picture.

Moreover, all medical witnesses at the autopsy who have expressed an opinion including all three pathologists, the radiologist, and the two medical photographers

have endorsed a much lower entry wound, just above the hairline at the right rear of the head.

An entirely independent kind of evidence for photo alteration is contained in the remarkably wide range of witnesses who did not see the stirrup (under the head) at the autopsy, but rather saw a block or chock under the head. These include the autopsy technicians, the FBI note takers, the photographers, and the embalmers. McDonald, who photographed the ARRB board members and who also worked at the morgue after 1963, recalled that he had never seen such a device used at a Bethesda autopsy. The autopsy personnel agreed with this. [Editor's note: Harrison Livingstone had made this point in 1992.]

The invisibility in the photographs of this lower entry wound, and the protests of the pathologists that it was originally obvious, only add to the probability that the photographic collection has been deliberately manipulated so as to eliminate this entry site. However, the matter does not end there. Even if this lower site were accepted, it would lead to impossible dilemmas for lone gunman advocates. The trail of metallic debris, lying more than 10 cm higher on the skull X-ray, would then immediately demand a second headshot, a conclusion that would deliver a mortal blow to the lone gunman theory. But for any conspirator who wished to change the verdict of history, such photographic manipulation would have provided an easy solution.

Moving the headshot up by 10 cm immediately circumvented the embarrassingly low entry site proposed by the pathologists, thus avoiding the insoluble dilemma of a second headshot. The difficulties of this new proposal, however, are discussed extensively below. Because they did not review the X-rays, this discrepancy between the high bullet trail and the low entry site did not trouble the Warren Commission. It first surfaced with the Clark Panel in 1968, when the X-rays were reviewed, and the problem persisted with the HSCA, which spent a good deal of time with the X-rays and much time trying to purge history of this alarming paradox. Nonetheless, the pathologists have stubbornly persisted, insisting that they got it right at the autopsy, seemingly unconcerned with the insoluble dilemmas that they generated by their stubbornness. This apparent lack of concern, however, came back to haunt them when they were deposed by the ARRB. (See the depositions of Drs. Boswell and Humes in the addenda.)

Dr. Boswell sketched the location of the large hole at the rear of the head on a skull for the ARRB. Douglas P. Horne has transcribed these as accurately as possible onto 2D views from several directions (Figure 9). These images speak for themselves: the large hole clearly extended deep into the occipital area. During my two conversations with Ebersole, after he described the entry wound just above the posterior hairline, I asked him where the large hole began. In remarkable agreement with Boswell's recent sketch (and also in agreement with Boswell's autopsy diagram), Ebersole located it at about one inch from the entry hole clearly in the occiput. A detailed optical density study of this same area on the frontal skull X-ray is also consistent with this conclusion. Finally, Finck, in his "Personal notes on the Assassination of President Kennedy" (1

February 1965) to his AFIP superior, Brig. Gen. JM. Blumberg, clearly stated that the wound did extend into both the frontal and the occipital areas.

Although a large hole was present at the right rear of the skull at both Parkland and at Bethesda, another question can be asked (as Lifton has done for decades): were the wounds the same at both hospitals? In their ARRB interviews, Sibert and O'Neill still insisted that Humes had asked about surgery to the head, and had never retracted this question while at the autopsy. Furthermore, the ARRB queried several Parkland witnesses about the V-shaped wound in the right forehead and none recalled this. Parkland physicians who have denied seeing such a V-shaped wound include Jackie Hunt, Ronald Jones, Malcolm Perry, Paul Peters, Don Curtis, Richard Delaney, and Adolph Giesecke. This "wound" is visible in the photograph of the throat wound (Figure 16), but a better view is the Groden superior profile (Livingstone 1992, photographs between pp. 432-433). The ARRB even asked Humes if he had made such an incision, but he denied it. This mysterious wound strongly supports Lifton's thesis that the body was altered between Dallas and Bethesda. Furthermore, witnesses such as Robinson (discussed elsewhere here), recalled seeing multiple, small, metal fragments in a container at the autopsy, reportedly taken from JFK. These fragments, of course, are no longer in evidence. For detailed photographs of partial bullets said to be from JFK, see Livingstone (1998, p. 562). Lifton has advanced other compelling arguments for such an illegal interception of the body between Dallas and Bethesda, which are not addressed here.

Conclusions: The Skull Wounds

1. Not a single witness at either Parkland or at Bethesda, ever reported the red spot seen in the posterior photograph of the head (Figure 1), the same site that the HSCA selected for the entry wound. Furthermore, the pathologists have stubbornly refused to authenticate this site, saying that it was far too high. Therefore, whether this red spot was subsequently inserted into the photographs (in the darkroom) or was rather some bizarre artifact, this "entry wound" is irrelevant to the case.
2. Virtually all witnesses recalled a large hole at the right rear of the skull, where the photographs show only well combed, slightly wet, hair, with intact scalp. In fact, no Parkland physician, on first seeing these photographs recognized 'them as authentic. Indeed, if the entire collection had been re-photographed, such alteration might not be detectable by photographic experts.
3. The skull sketch (Figure 5) that Humes prepared for the Warren Commission (with Harold A. Rydberg as artist) showed the large hole extending far posteriorly, into the occiput just as the pathologists and virtually all of the eyewitnesses have reported. The X-rays are also consistent with this interpretation, particularly when it is recognized that a flap of bone at the rear of the skull could move in and out like a trap door, so that the back of the skull could take on varying appearances, depending on exactly how far this bone flap had swung open. This bone flap was actually described by McClelland, and can be seen on the frontal X-ray, where the hinge appears as a complete fracture line (see McClelland in Figure 2C). [Editor's note: For more discussion of this issue, see Assassination Science 1998, pp. 331-332.]
4. The location and size of the scalp defect is less certain. No additional photographs exist to resolve this issue. I tend to side with the morticians, who, because of the nature of their work, would have known the real state of affairs. They report that the scalp could not be closed in this area. In his ARRB deposition, Humes also recalled that several centimeters of posterior scalp remained open. Since no scalp fragments were later recovered, this seems a reasonable conclusion.
5. By utilizing the skull X-rays, the previously mysterious F8 photograph (see the Postscript) can now be interpreted as the back of the head. This should be no surprise because the pathologists' initial inventories actually described this view as posterior skull. This analysis is consistent with the eyewitnesses and is also remarkably consistent with the X-rays.
6. The above interpretation of F8, in turn, suggests a site of origin for the Harper fragment (Figures 2A-2D), an unexpected bonus not likely to result from a false interpretation of F8. When the Harper fragment is placed into this site, an astonishing event occurs. The Dallas pathologists (who actually called it occipital bone) identified a probable lead deposit on this bone. After my placement of the Harper fragment, this site of lead lay eerily close to the Bethesda pathologists' rear entry wound.
7. In agreement with Lifton's thesis, the body was probably altered between Dallas and Bethesda. The bizarre tracheotomy seen at Bethesda seems to me the

strongest argument for such unlawful activity, but the evidence from the head is also persuasive, as discussed above.

Did a Bullet Strike the Skull from the Right Front?

At the news conference at Parkland Hospital immediately after the assassination, Malcolm Kilduff, the assistant press secretary (Pierre Salinger was over the Pacific with several cabinet members, leaving Hawaii for Japan), was asked about the cause of death. He stated: " Dr. Burkley told me, it is a simple matter ...of a bullet right through the head." The striking feature of his response, however, was the non-verbal portion: as he made this statement, he pointed toward his right forehead, indicating the entry site. A photograph (Figure 10) captured this gesture at the critical moment. A follow-up question asked: "Can you say where the bullet entered his head, Mac?" To this Kilduff replied: "It is my understanding that it entered in the temple, the right temple." Later that day, Chet Huntley repeated this: "President Kennedy, we are now informed, was shot in the right temple. 'It was a simple matter of a bullet right through the head,' said Dr. George Burkley, the White House medical officer." (Vincent Palamara, JFK: The Medical Evidence Reference 1998, p. 44.)



Figure 10. Whitehouse acting press secretary, Malcolm Kilduff, points to his right temple in response to a reporter's question as to where the President was hit.

Others corroborate this location, such as Seth Kantor (20H353), ¹⁵ a Scripps Howard reporter whose notes stated: "interred (sic) right temple." Charles Crenshaw, M.D., ¹⁶ one of the treating physicians in Trauma Room One, demonstrated on live television for Geraldo Rivera ("Now It Can Be Told," 2 April 1992) just where this shot entered: near the hairline, just above the lateral border of the right eye socket. [Editor's Note: This video clip is included in my video, "JFK: The Assassination, The Cover-up, and Beyond."]

David Stewart, a physician not called before the Warren Commission, perhaps because he had given public talks about the frontal shots, had been present for the treatment of all three of JFK, Connally, and Oswald. When asked about the fatal shot to JFK, Stewart responded:

Yes, sir. This was the finding of all the physicians who were in attendance. There was a small wound in the left front 17 of the President's head and there was a quite massive wound of exit at the right backside of the head and it was felt by all of the physicians at the time to be a wound of entry which went in the front ... (Harold Weisberg, *Post-Mortem* 1969, pp. 60-61.)

Other Parkland physicians who clearly support a frontal headshot include Robert McClelland, Ronald Jones, Donald Seldin, and Gene Akin (Vincent Palamara, *JFK: The Medical Evidence Reference*, 1998).

Tom Robinson, the funeral home employee who restored JFK's head, described a wound, about 1/4 inch across, above the right eye, near the hairline, where he had to place wax to disguise it. He added that this wound was so close to the hairline that the hair could easily cover it, which may explain why more witnesses did not see it. And Joe O'Donnell, who viewed autopsy photographs within the first week, witnessed an obvious wound above the right eye in a photograph, which he interpreted as the entry for the bullet that had caused the large hole at the right rear.

But the most objective evidence for precisely such a frontal shot lies on the skull X-rays. It should first be noted that the trail of debris obviously does not match a bullet entry near the external occipital protuberance (EOP), the site preferred by the pathologists. Essentially no one, except for the three pathologists, (and the photographers and the radiologist) believed in a single headshot that entered at such a low site. (My own view is that one headshot did enter near the EOP, just as the pathologists said, but that there was also a subsequent, frontal shot.) Instead current, lone gunman advocates now necessarily support the HSCA's much higher entry wound (the red spot).

But this does not work, either. First, the lateral X-ray (Figure 11) shows the 6 .5 mm fragment lying one centimeter below the "entry" site (which lies where the skull has been fractured), but the trail of debris is noticeably higher than even this "entry" site and even higher than the 6.5 mm object. No lone gunman supporter has ever explained this discrepancy: it is simply ignored. Even worse, though, the Warren Commission claimed (17H257) that the nose and tail of this bullet were found inside the limousine, meaning that this supposed bullet cross section must have come from inside the bullet (sic). Although no ballistics expert has ever seen a cross section from the outside of a bullet deposited at an entry site, the Warren Commission has done better than that. By placing an internal cross section not at the entry site (but one centimeter inferior to the entry site), they have surpassed all prior case in two separate measures at the same time, a truly remarkable achievement. (See Bonar Menninger and Howard Donahue, *Mortal Error* 1992, p. 68.)

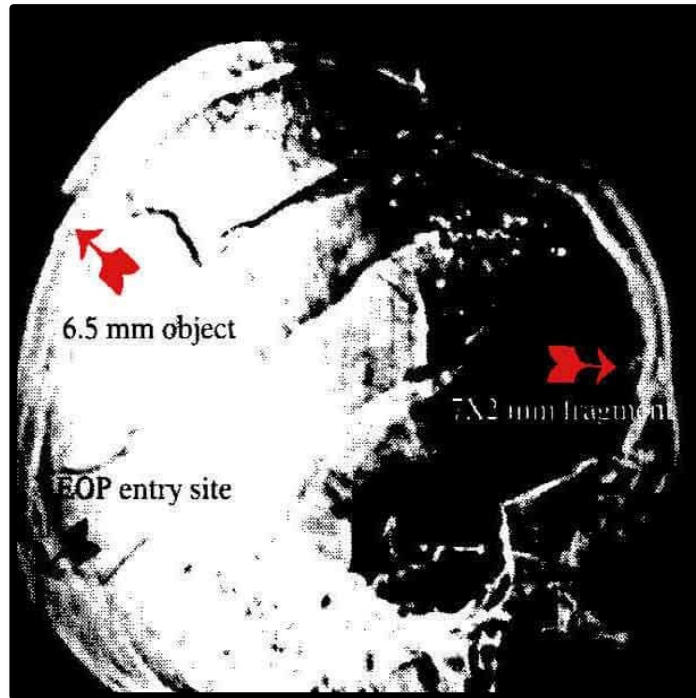


Figure 11A. Lateral autopsy X-ray Note the trail of metallic debris across the top of the skull, at least 10 cm above the occipital wound that the pathologists identified.

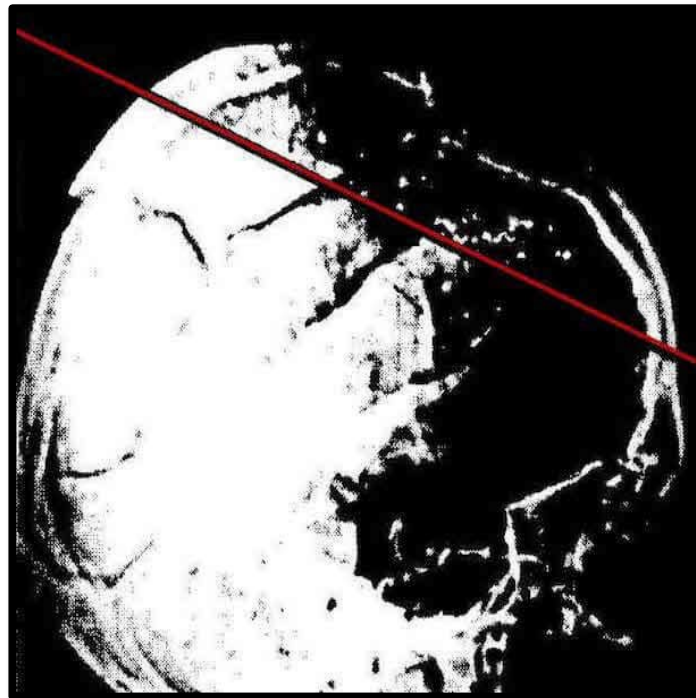


Figure 11B. Lateral autopsy X-ray, showing direction of X-ray beam used for frontal X-ray.

Although no proposed, posterior entry site matches this trail of metallic debris, on the other hand, a bullet that entered the right forehead, near the hairline, directly over the outer edge of the right eye socket, would match this bullet trail with remarkable precision. Furthermore, a close look at the frontal view on the diagram that Boswell

drew for the ARRB (Figure 9A-D) shows a notch in the frontal bone at just this site (where the bullet entered). As further confirmation that this notch is no accident, examine Boswell's sketch from the night of the autopsy (Figure 4A). The notch is also there!

When I examined the frontal X-ray, I used a bright light to highlight the outside of the skull. I could then easily see the top edge of the remaining frontal bone (high in the forehead). Furthermore, with the optical densitometer, I measured the transmission of light above and below this edge over a long distance.

The area above the (supposed) bone edge was darker (and the optical density values higher), implying less bone, whereas the area below it was lighter (the optical density values were lower), which implied residual frontal bone. These measurements therefore verified what I had seen with my naked eyes with the bright light, I had identified the edge of the frontal bone. I could now trace the remaining frontal bone with good accuracy. This sketch is shown in Figure 12 the same sketch that was published in 1995 (Livingstone 1995, p. 101), well before Boswell made his sketch for the ARRB. The same notch is also shown in my X-ray based sketch. This notch is therefore a critical piece of evidence: the frontal bullet knocked out a small fragment of bone here.

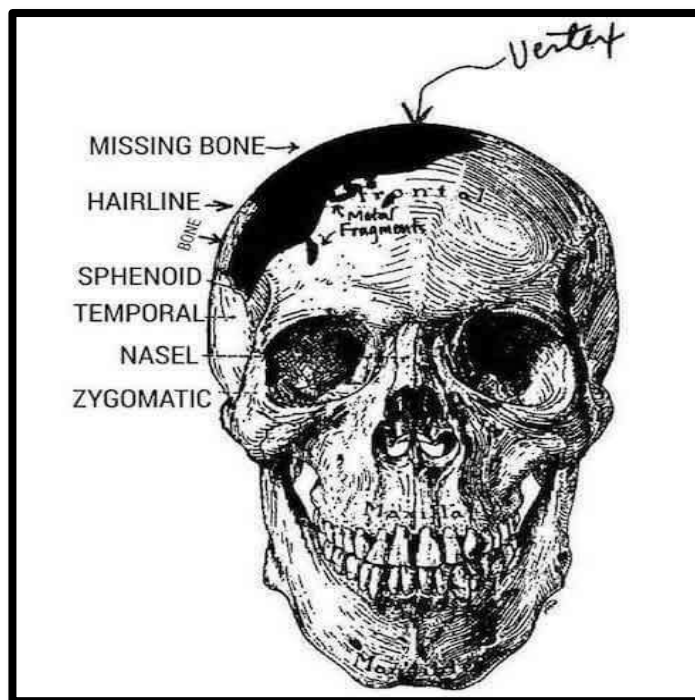


Figure 12. Residual frontal bone: Mantik's analysis of the skull

In summary, the X-rays, especially in conjunction with Boswell's sketches, provide powerful confirmation of a shot from the front. Five lines of evidence support such a frontal shot, near the hairline, above the outer border of the right orbit:

1. A wound was seen in the scalp (attested to by Kilduff, Crenshaw, Stewart, McClelland, Akin, Kantor, and O'Donnell)
2. The notch in the frontal bone was still recalled by Boswell for the ARRB.

3. The notch is actually seen on the X-rays.
4. The trail of metallic debris on the X-rays is more consistent with such a frontal shot than with it is with any posterior shot proposed to date.
5. Close examination of fragments in this debris strongly suggests that, overall; the larger ones are located closer to the rear. This would be expected for a shot from the front (but not for a shot from the rear) because the larger ones initially contained more energy (energy is proportional to mass); they should have traveled farther.

One other point should be emphasized. Boswell's unprompted recall of this subtle detail (of the notch) for the ARRB, after so many years, raises the question of whether he understood, at the autopsy, just what this site represented. If O'Donnell's recall of such a wound is correct (he saw this

wound in an autopsy photograph), then Boswell very likely recognized (tacitly) evidence for a second headshot. Unfortunately, this question was never put to any of the pathologists or to any other eyewitness, for that matter, not even by the ARRB.

One more question should be asked. Where could a frontal shot to the right forehead/temple have originated? The traditional answer of the grassy knoll does not fit well, because such a trajectory should have traversed the left- brain. (Whether a shot missed from the grassy knoll is a separate issue, not discussed here, because it is outside the purview of the medical evidence.) However, a shot from the north storm drain at the top of the overpass is far more feasible (Grant Leitma, "Where Did the Front Shot come from?" Fourth Decade, November 1993, p. 31). For such a bullet to exit through the right rear of the skull, however, an additional sideways deflection on striking the skull would appear necessary. Such a deflection may be reasonable, however, especially since the skull surface is sloping where this bullet entered, and this slope would lend itself to such a sideways deflection.

The Back Wound

It was Commission member Gerald Ford who initially elevated this wound to the back of the neck in order to salvage the SBT. (See Assassination Science 1998, p. 177.) Supporting a wound in the back of the torso (rather than the back of the neck) were the following: the pathologists' official autopsy report, the Sibert and O'Neill report, Boswell's autopsy diagram, the autopsy photographs, and the eyewitnesses. All of these agreed that the back wound (Figure 2) was in the, back of the torso, not the back of the neck. The one exception to this remarkable agreement is Boswell's second opinion: after he was asked to reconsider his original autopsy drawing (Figure 4B), he agreed to elevate the back wound. By doing so, he denied the accuracy of his own autopsy diagram!

On seeing this change, Francis O'Neill, one of the FBI agents at the autopsy, ridiculed Boswell for this convenient after-the-fact change of mind. It should also be noted that Admiral Burkley initialed Boswell's diagram as approved (see his signature in Figure 4B), so if Boswell indeed had grossly misrepresented the back wound in his own diagram, then Burkley, too, had been gravely mistaken. That both physicians would have made such a grievous error seems unlikely. When Boswell was

first questioned by the ARRB, he first said that this wound lay at a cervical level, but when shown the autopsy photograph he opted for T2!

Admiral George Burkley's death certificate (dated 23 November 1963) placed this wound at T3 (the third thoracic vertebra). Burkley's choice of T3 raises a serious question. It is not likely that he would merely have glanced at the body and made this correlation by himself. More likely, he obtained this information from the pathologists, either at the autopsy, or during the next day when the autopsy report was being written. Ebersole, in my conversation with him, actually placed the wound at T4. Ebersole's comments must be taken seriously because his specialty (like mine) was radiation oncology. This is the sole specialty in which correlation of internal anatomy with external anatomy is essential, if this is not done correctly, the tumor will be missed by the therapeutic X-ray beam. The levels of T3 and T4, although noticeably lower than the top of the scapula, do receive surprising support from other sources. Of these sources, the shirt and coat are the most intriguing. According to Robert Frazier of the FBI (The Warren Report 1964, p. 92), the hole in the shirt was 5 3/8 inches (13.65 cm) below the top of the collar; the hole in the coat was 5 3/4 inches (13.8 cm) below the top of the collar. My own measurements at the Archives agreed closely with these. An excellent photograph of the shirt can be seen in Weisberg's *Post-Mortem* (1975, p. 597); for the coat, see Livingstone (1998, pp. 24-25) or Groden (1993, p. 78). While at the Archives I had a 6' 4" live, male model (S. M.) put the coat on. I was struck at how low this 'hole actually was by both palpation and visual inspection; the hole was about 10 cm (four inches) below the scapular spine! There is a horizontal seam in the coat across the top of the back; I could feel the top of the scapula at 2-3 cm above the seam, whereas the hole laid an additional 7-8 cm below the seam. Additional evidence for such a low back wound has been previously compiled. (See *Assassination Science* 1998, pp. 110-111.) If this evidence is correct, then the photograph of the back wound has been altered.

Several witnesses, however, including Humes, place the back wound much higher than this at the top of the scapula, which would be consistent with the photograph (Figure 2). To correlate this level with a particular vertebral body, normal anatomy is shown in Figure 13. In this photograph, the top of the scapula would lie between T1 and T2. Standard anatomy textbooks place the scapular spine (the visible horizontal portion near the top) at about T2 (Carmine Clemente, *Anatomy, A Regional Atlas of the Human Body* 1987, Figure 140). Anatomy textbooks (Clemente 1987, Figure 591, and J. C. Boileau Grant, *Grant's Atlas of Anatomy* 1972, Figure 458), place the 3rd or 4th tracheal ring (the level of the throat wound) 18 at about C7. So even when coupled with a back wound at the higher level of T1 or T2,

however, the level of C7 for the throat wound is devastating to the SBT, the back wound is then obviously lower than the throat wound! For these two wounds to connect, Oswald would have had to shoot from the trunk of the limousine. It is not difficult to imagine why Ford felt compelled to give the SBT a modest assist. The upward direction (from back to front) of a line connecting the back wound to the throat wound was apparently demonstrated by transit probes at the autopsy for which photographs no longer exist, but which so many observers recall. So even if the photographs of the back wound are accepted as authentic (and the wound were at T1 or at T2), there

is still a very serious problem for the SBT. However, if the evidence listed above for an even lower back wound (i.e., T3 or T4) were correct, then the SBT would be flagrantly ridiculous.

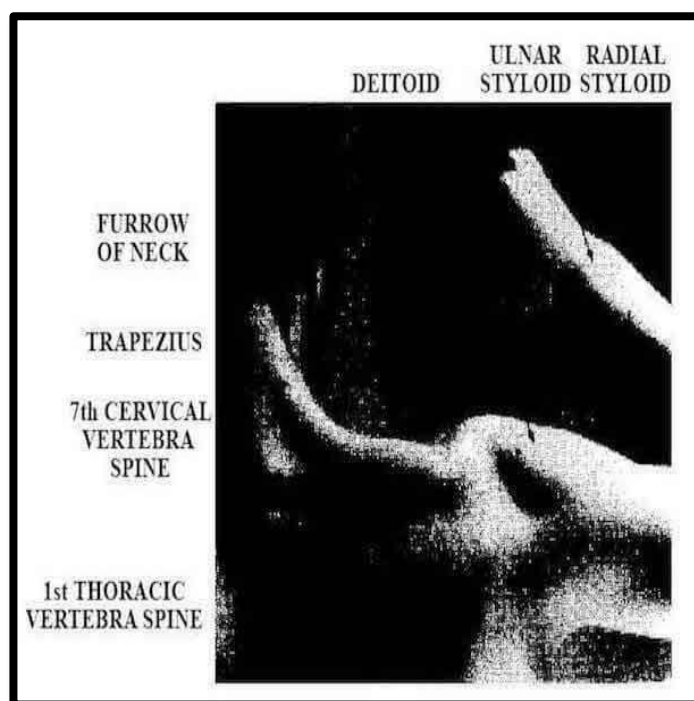

Figure 13. Normal anatomy of the back (D. W McKears and R.H. Owen, Surface Anatomy for Radiographers. (1979), p. 41)

The above arguments apply within a vertical plane, but equally powerful arguments against the SBT apply within a horizontal plane. The first individual to recognize this paradox was John Nichols, M.D., A pathologist at the University of Kansas, (John Nichols, "The Wounding of Governor John Connally of Texas," The Maryland State Medical Journal, October 1977). He drew a model cross section of anatomy, and concluded that a bullet fired from the lateral angle of the sniper's nest simply could not exit at the midline of the throat without striking bone. And since the X-rays at this level show at most minor trauma to the transverse process of T1, this trajectory could be ruled out, according to Nichols.

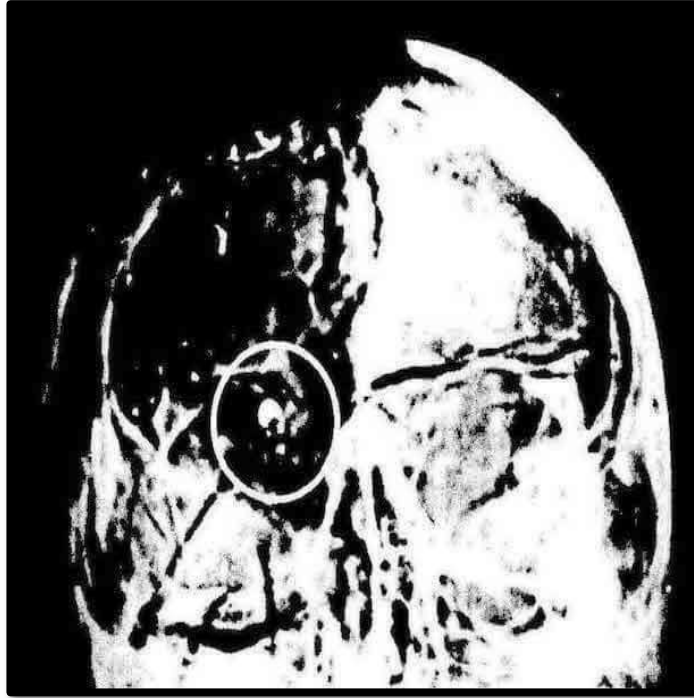


Figure 14. Frontal Autopsy X-ray... The largest "metal" fragment, a 6.5 mm object that lies inside the right orbit (circled) was added later in the darkroom.

The ideal test would be a CT scan of JFK's body, but CTs were not yet available. A set of frontal and lateral X-rays might have done almost as well, but no lateral autopsy X-ray exists. So I did the next best thing. I took detailed measurements from the frontal X-rays (at the Archives) through the upper back and lower neck. Then I located a real CT scan of a patient similar in overall size to JFK. When these measurements were integrated with this CT scan, it was obvious that the HSCA trajectory was highly unlikely. [Editor's note: This experiment is reproduced elsewhere in this volume.]

If the bullet had transited at mid-T1 or above, it would have struck bone (the lateral processes of the vertebrae) and caused major fractures (that are clearly not seen on the chest X-ray). On the other hand, if it had transited at a lower level, it would have passed through the lung, causing air to escape into the chest cavity (i.e., a pneumothorax). Although the pathologists saw a bruise at the top of the lung, they saw no penetrating wound in the lung itself. The bullet, therefore, did not pass through the lung. Additional arguments against the SBT, based on the location of the back wound at five centimeters from midline, have previously been described (Assassination Science 1998, pp. 102-103), and will not be repeated here. In summary, then, powerful arguments, in both the vertical and horizontal planes show how the SBT violates both common sense as well as basic anatomy. These issues were never addressed, let alone explored, by the Warren Commission, or even by the HSCA.

What caused the (non-penetrating) back wound? There is fairly compelling evidence that it was either the first shot fired, or the first shot to hit JFK. Roy Kellerman (Palamara 1998, pp. 105-108) recalls that when he turned around he saw JFK put his hand up (on his back) and that he also heard JFK say: "My God, I am hit!" O'Neill included this comment by Kellerman in his FBI report. He later recognized how important it was

because it violated the SBT. O'Neill therefore considered this to be a crucial remark by JFK. The whereabouts of this bullet, or whether it was ever recovered, is still debated. Years later a sabot was found on the roof of an adjacent office building (Sloan 1993, pp. 111-112), thus raising the possibility that an attempt had been made (with an underpowered round) to plant a Mannlicher-Carcano bullet on JFK. Other possible causes for the back wound include:

1. Shrapnel from a bullet that struck the street or sidewalk.
2. A piece of the pavement that was launched by a bullet that struck the street or the sidewalk (Palamara 1998, pp. 213-214)
3. A bullet that first struck the seat back of the limousine and then shattered or exploded.

(Ed O'Hagan is currently doing a photographic analysis of this latter possibility, while Roy Schaeffer had previously pointed out a possible bullet hole in the seat back (behind JFK) in photographs taken of the limousine at the White House garage.) If the spectroscopic evidence is accepted, then:

1. The projectile that entered the back was metallic (copper residue was found on the clothing)
2. The projectile that entered the throat was not metallic (no copper residue was found on the clothing).

According to The Warren Report, the nose and tail of this bullet were found inside the limousine; therefore, this cross section must have come from inside the bullet, which is an undeniably preposterous proposal. The situation is even worse than this, however. One of the bullet fragments found in the limousine (and still in the Archives) has its copper jacket

peeled back by almost 180 degrees. How this could happen, merely by striking skull, is almost miraculous. On the other hand, if the bullet had first struck pavement, then such a peeling back might occur, but that would mean one additional bullet. The Commission could consider none of these options because any one of them would have meant conspiracy (too many bullets).

The Throat Wound

Malcolm Perry, M.D., the ENT surgeon at Parkland, thrice described this small, smooth, round wound as an entry wound during the press conference at Parkland on 22 November 1963. (See Assassination Science 1998, Appendix C.) Within the week after the assassination, virtually all of the Parkland doctors agreed that this had been an entrance wound. Margaret Henchcliffe (6H141-143), one of the E.R. nurses, said that she had never seen an exit wound that looked like this. However, according to Charles Crenshaw, M.D., after a visit by the Secret Service following the assassination, the doctors seldom discussed the assassination among themselves. Moreover, their testimony before the Warren Commission changed drastically, even though they had seen no new evidence with their own eyes.

At the autopsy, the pathologists did not describe this wound, even though Perry maintained that he had left the wound "inviolated," i.e., still readily visible. It seems quite certain now that this ignorance of the bullet wound by the pathologists was merely feigned, because the pathologists knew that the lone assassin theory was in vogue and that such an obvious entry wound would contradict it. Also, even if they had wanted to connect an entering bullet from the back to the throat wound (as a supposed exit site), they knew well enough (from everything they had seen at the autopsy) that the back wound was far too low for this to work.

Humes claimed that he first learned of the throat wound from Perry, when they spoke by telephone after 8 AM Saturday morning, November 23. It is curious, however, that Perry, in his subsequent Commission testimony (6H16), seemed uncertain about the timing of this call, first recalling that it was Friday afternoon! It was only after he was prompted that he agreed to the Saturday morning scenario. Perry may also have been subjected to pressure to change his conclusion about a bullet entry into the throat. Graduate student James Gouchenaur (HSCA File# 180-10109), on 1 June 1977, recalled a conversation with Secret Service agent Elmer Moore, who expressed remorse for badgering Perry into changing his testimony about the entrance wound in the throat. Audrey Bell also told Livingstone that Perry had received calls during the night from Bethesda (Livingstone 1995, p. 192)

The list of autopsy witnesses who knew of the throat wound is surprisingly long and has been meticulously assembled by Kathy Cunningham, L.P.N. Now, however, after Boswell's admission to the ARRB that he did know of this projectile wound while at the autopsy (it is clear that he was not merely referring to the tracheotomy), the evidence of all of these witnesses is scarcely needed any more.

Based on a telephone call during the autopsy, Ebersole, the radiologist, told me (see Appendix E) that the projectile wound to the throat was already known at the autopsy. It is noteworthy that tissue samples were taken of the tracheotomy wound, a procedure that makes no sense at all for a simple tracheotomy.

Many witnesses have described seeing probes in the body during the autopsy (or sometimes in photographs of the body), and that these probes passed through the tracheotomy. For a simple tracheotomy to be probed also makes no sense, but if a bullet wound were located there, then both a probe and tissue samples would make sense. I shall say no more about this feigned ignorance of the pathologists, because the evidence contrary to this charade is now simply overwhelming.

Instead, the relevant question is: what caused the wound and where did the bullet go (if there was one)? The traditional scenario for why the X-rays showed no metal debris (in the throat) is that the bullet (or fragments) was removed surreptitiously. That the tracheotomy wound changed dramatically between Parkland and Bethesda seems likely. When first asked about this by David Lifton, Perry replied that the tracheotomy was only about 2-3 cm across, but when pushed on this question, Perry successively increased the width until now he seems unwilling to deny that the gaping, irregular wound in the photographs is entirely his work (Lifton 1988, Chapter 11). In his Afterward, Lifton listed medical eyewitnesses from Parkland who agreed that the tracheotomy wound was not at all what they remembered (others could now be added). Perry's own, initial,

surprised reaction on seeing the photograph of his (supposed) tracheotomy is especially noteworthy (see Lifton's Afterward). Now, however, he seems not to care anymore, as he wrote to James H. Fetzer (16 February 1998):

I don't wish to relive that tragic weekend, and I avoid reading about it (sic)... I don't believe there is credible evidence of a "cover-up," nor does anyone I know think so... Most of us view the conspiracy theories as mainly self-serving, usually based on distortions and selected interviews with people who had little or nothing to do with the actual events, and invariably coupled with an ignorance of medicine and trauma. I find that I really don't care anymore because I know what the truth is and that's sufficient.

Charles Crenshaw has strongly insisted that the tracheotomy in Parkland was much smaller, not at all like the one in the photographs. (Boswell's autopsy diagram clearly states the diameter as 6.5 cm; see Figure 4B.) Crenshaw also reminded the ARRB that the flange on the tube was 5 cm and that the wound was, it almost necessarily had to be smaller than that. David Lifton's own research (1988, Chapter 11) has suggested that the flange was even smaller than this, possibly 4 cm or even as small as 3 cm. The wound in the photographs is certainly much larger than that. For the Commission, Humes even described it as large as 7 to 8 cm, although for JAMA he described it as only half that size.

A new witness to this question has recently emerged, someone who was in Trauma Room One, a medical student at the time, Joe D. Goldstrich, M.D., 19 more recently from San Diego, California. When he was asked about this specifically (Sloan 1993, p.8-9), he recalled his initial impressions on seeing the autopsy photographs: confusion and consternation. He said: "The whole front of his neck was wide open. It had simply been filleted." Ebersole also expressed to me his near horror at seeing such a large and irregular tracheotomy.

The widened and ragged appearance at the autopsy of this supposed mere incision strongly suggests that the tracheotomy was enlarged, perhaps during a search for bullets or for metal debris prior to the autopsy. There is, however, no certain way of knowing what, if anything, was found. Curiously, Livingstone (1998, p. 562) reproduced detailed photographs (including some documentation for them) of partial bullets, 'said to have been removed from JFK. Nothing is said, however, about whether these were from the skull or from the throat.

The primary argument against such a frontal bullet to the throat is the minimal trauma seen in the spine (on the X-rays), as well as the absence of a corresponding exit wound in the back. Although there is a probable (tiny) fracture to the right lateral process of T1 on the X-rays, that is all. It is not even certain whether this fracture was present before the shooting. The direction of such a proposed shot also poses serious difficulties, the autopsy evidence strongly suggests that it was traveling diagonally from left to right, consistent with a shot from the left front. Even worse, though, its remarkably limited range is puzzling, because most ordinary bullets would, without striking bone, easily have passed through the chest and exited from the back. This one apparently did not.

As I contemplated this paradox some years ago, I realized that any radiolucent object (i.e., something invisible on the X-rays) would be consistent with all of the evidence.

And then I wondered, if there really had been a complete hole in the windshield (Larry Sneed, *No More Silence* 1998, pp. 147-148), was it possible that a fragment of glass had caused the throat wound? It met all of the requirements: it was radiolucent, it had a limited range, the pathologists (probably) would not have seen it, and, furthermore, the bullet might even have come from the right front. In particular, spray of glass particles, diverging in a cone (even from a right front shot) might have permitted some of them to strike JFK in a left to right direction. 20

A close examination of the Altgens photograph (taken at about Zapruder frame 255) shows that a path from the windshield to JFK's throat was entirely unobstructed. This seemed an uncanny corroboration for this proposal. Furthermore, some versions of this photograph show a mark (resembling a spiral nebula with a dark hole in the center) in the windshield that could be a through and through hole. [Editor's note: Roy Schaeffer detected this feature in this photograph (*Assassination Science* 1998, pp. 143-144). Schaeffer has also summarized his conclusions in an unpublished manuscript, *The Slaying of Camelot*.] It was only recently, however, on re-reading the comments of Tom Robinson (from Gawler's funeral home), that I became conscious of possible additional evidence for this proposal.

Robinson described three tiny holes in the right cheek, near the right eye. I had previously ignored these, because I could not relate them to anything else. The reason that Robinson recalled these at all is because the fixative solution was leaking from them. Such wounds could hardly have been caused by debris coming from inside the cheek: the distance from sites of major trauma in the brain was too remote. Furthermore, bone would have obstructed such a path from the brain. Instead, something must have struck JFK's cheek from the outside. But no other limousine occupants had suffered similar injuries, so why just JFK?

If tiny fragments of glass had been emitted in a small cone of scattering (a small cone is the likely scenario, because of the bullet's initial high speed), then it is possible that JFK, and no one else, would have been hit. This conclusion is based on JFK's position in the Altgens photograph, and also on the presumed angle of incidence of the bullet. Douglas Weldon, J.D., has recently informed me that he is aware of further, current research on this very question. [Editor's note: Weldon reviews windshield evidence elsewhere in this volume, listing several, independent witnesses who recalled a through and through hole in the windshield.]

Moreover, witnesses to the windshield hole (Palamara 1998, p. 63) often described a specific and consistent site that matches the site seen in the Altgens photograph. In the present volume, Weldon introduces the Ford Motor Company employee (whose audiotope I have heard) who saw the windshield and the hole before the windshield was destroyed. Based on his inspection, this employee concluded that the shot had come from the front. As further corroboration of his veracity (he was not versed in the assassination literature), he placed the hole at the proper site. Weldon also reviews the seemingly inconsistent testimony of government employees who examined the windshield at different times, which suggests that they were examining different windshields. Robert Livingston, M.D., has advised me (and others, too) that when he worked at the National Institutes of Health in 1963, he had heard of orders for multiple windshields. Like Weldon, he, too, has wondered if the original windshield was (illicitly)

substituted. [Editor's note: See Assassination Science 1998, pp. 165-166.] The windshield currently stored in the Archives does not contain a through and through hole.

Weldon lists several witnesses who recalled a shot from the left front, probably from the storm drain on the south overpass. At present, that drain has been covered over, but in 1963 it was open. Its location mirrors a similar drain site on the north overpass, the one that I have proposed for the origin of the shot to the right forehead. Furthermore, Weldon adds that the image in the Cancellare photograph seems to show someone holding a rifle at this site. None of this information ever came to the attention of any government inquiry.

Weldon's proposal has more than one attractive feature. First, it may explain the odd, almost unique, fireworks like sound of the first shot that so many witnesses recalled. Weldon has learned that a shot passing through a windshield sounds just like fireworks going off. Furthermore, such a shot would have the proper left to right trajectory, although it could still not explain the limited range of such a bullet, as implied by the autopsy findings of non-transit. In addition, if a shooter really had fired from the left front it might explain the odd reports of several witnesses who described a left temple entry wound. These include physicians McClelland, Jenkins, Giesecke, the priest Oscar Huber, photographers Altgens and Similas, and recently, Hugh Huggins (aka Hugh Howell) Robert Kennedy's emissary to the autopsy (Sloan 1993, p. 183). One more witness is Lito Porto, a neurosurgery resident under Kemp Clark (Palamara 1998, p. 75). For a discussion of the left entry wound, see Lifton (1988, pp. 45-47).

Crenshaw had recalled that the left temple, after removal of a blood clot, had shown no underlying wound. I had found this to be persuasive evidence against such a left temple shot and had therefore discarded this possibility. But now I am less certain. On the other hand, knowing how easy it is to reverse left for right (as I have done many times in this case, as also did Robert Blakey, on national television), I naturally wonder if some of these witnesses merely reversed left for right and that most of them had actually seen a shot to the right temple/forehead.

Such a shot from the left front, however, might explain marks found on the north sidewalk along Elm Street, as Weldon notes. A successful shot to the left temple would actually match the large hole at the right rear better than a shot from the right front, although the metallic debris on the X-rays would still strongly support a right frontal shot. But perhaps the question should be changed. Is it possible that yet a third shot struck JFK's head? It is difficult for me to believe that three shots struck the head in such a short time interval, but I admit that, with the available evidence, I cannot totally rule out this possibility. If the current X-rays could be thoroughly scanned in great detail, it is possible that a third shot could be excluded or perhaps even confirmed.

For the throat wound, therefore, some uncertainties remain. Was it caused by a bullet (of remarkably limited range) or instead by a glass fragment? Was this shot fired from the left front (consistent with the observed trajectory), or from the right front (which might have ejected a glass fragment with the required trajectory, the observed short range and the requisite invisibility to X-rays)? It is not likely, short of exhumation, which might or might not be sufficient, that these issues can ever be entirely resolved.

There is one final question, however. If a glass fragment caused the wound, then where did the bullet go? There are two possibilities: either:

1. It struck somewhere inside the limousine (either staying inside or possibly exiting)
2. It struck somewhere outside the limousine.

The available evidence may be consistent with either interpretation. Many witnesses, reported by the Warren Commission (also see Menninger 1992, pp. 68-74, for a discussion of such ricochet bullets and the witnesses who saw them) either saw or heard bullets strike the street and the surrounding turf, some in front of the limousine and some in back. ²¹ The Commission ignored these witnesses, but their testimonies were nonetheless included in the volumes of its Hearings.

Alternately, the bullet could have struck inside the limousine. Roy Schaeffer, using an enlargement of a photograph of the inside of the limousine (taken at the White House garage), believes that he has identified a bullet hole in the rear seat, near Jackie's elbow. Could this hole conceivably represent a left frontal shot that was deflected after striking the windshield?

Whether such a bullet stayed inside the limousine or exited and (possibly) struck the street remains uncertain. What is known, without any doubt, is that the Secret Service was astonishingly protective of the limousine in Dallas after the shooting. Several witnesses even saw them tear the film from a young boy's movie camera after he had photographed the limousine interior at Parkland Hospital. The premature disappearance of the limousine, in the immediately subsequent days (as discussed by Weldon), is also suspicious. It would seem that a more determined attempt was made to destroy evidence than to preserve it. If the limousine did contain evidence of conspiracy (either from bullet holes in the upholstery or even in the windshield, or from physical bullets or fragments), then such efforts would have been expedient (as part of the cover-up).

The Brain(s)

Initially, I did not know whether the skull contained any brain tissue at all at the autopsy, partly because of the comments of several autopsy personnel, but also because of surprising evidence that the skull may have been (illegally) explored before the autopsy (Lifton 1988). After reflecting on this question, however, I eventually recognized that the X-rays might hold the answer. In due course I was able to address this question both by means of an experiment and also by repeated measurements of optical density (OD) performed on the X-rays at the National Archives. The conclusions were quite straightforward:

1. There really is a brain within the skull as seen on the X-rays.
2. It is totally incompatible with the photographs of the brain (I have repeatedly viewed these photographs myself, even using a stereo viewer at the National Archives);

3. The amount of residual brain, along a measured line of sight, varies in different parts of the X-rays from as low as 25% to as high as 90%, but on the right side (which shows the least brain tissue) is often between 30 and 60%.

The most surprising result, though, was the loss of brain tissue on the left side (only 2/3 to 3/4 remains), and the virtually total absence of brain in a large bilateral area at the front, the large void that Humes describes in his excerpted testimony (see the addendum). In addition, I was able to demonstrate that the area of the right cerebellum showed only about 25- 30% of the expected amount for a totally intact brain, thus confirming the descriptions of the Dallas physicians that this area had been severely traumatized. These X-ray observations of the cerebellum also disagreed radically with the photographs, which showed an almost normal cerebellum. In the laboratory, using a real skull and simulated brain material (used in departments of radiation oncology), I was able to explore these issues in more detail and at some leisure. By taking X-rays of skulls variously filled with simulated brain tissue, and then taking measurements on these X-rays, the resulting OD data provided strong confirmation for the conclusions I had reached from the extant JFK X-rays.

While at the National Archives, I answered one additional question: was it possible that much of the brain was actually present, but had been displaced to the outside of the skull? By passing a bright light over the entire circumference of the skull, I was able to see even small amounts of soft tissue that would otherwise have been invisible. Since, except for scalp, I saw essentially no such soft tissue here, the conclusion was obvious, and the missing brain was not outside of the skull. During his ARRB interview, Humes also agreed that brain was not visible outside of the skull.

Therefore, the chief paradox persisted: a truly huge amount of brain was missing, in gross contradiction with the photographs of the brain. I could only conclude that the brain photographs were not those of JFK. Indeed, after examining all of the eyewitness evidence from Parkland and from Bethesda, and surveying the publicly available image of the brain, Robert B. Livingston, M.D., a world authority on the brain and founder of the Department of Neuroscience at U.C San Diego, came to the same conclusion. (See *Assassination Science* 1998, pp. 161-166).

Although Livingstone (1995, p. 261) had proposed that the brain had been switched, what no one had yet considered, perhaps because it seemed so disgraceful, was the possibility that there had been two different brain examinations, of two different brains, on two different occasions.

However, on reviewing the new evidence uncovered by the ARRB and integrating this with previously available information, Douglas P. Home, Senior Military Analyst for the ARRB, proposed precisely that. He assembled a large number of disparate pieces of evidence, all of which were strikingly consistent with this proposal. He offered three separate lines of evidence for his stunning conclusion:

1. Timeline conflicts
2. The visible appearance of the brain at the two different dates.
3. Discrepancies in the film and photographic techniques employed. [Editor's note: Home's study may be found elsewhere in this volume.]

Evidence from the X-rays that I had obtained prior to the activities of the ARRB constituted yet a fourth pillar for this surprising discovery. In view of Home's accessible study (in this volume), I present here only the tables (Tables 1-4) that summarize all of this evidence. When viewed in this fashion, the case for two brains is quite remarkable. It is difficult, in retrospect, to imagine an alternate explanation that can reasonably explain so many odd details.

Table 1:

- Time line Conflicts
- Evidence for an early brain exam (c. 11/25/63)
- Boswell to HSCA: the exam was 2-3 days after 11/22 Stringer to HSCA: the exam was 2-3 days after 11/22 Boswell: Finck was absent
- Stringer: Finck was absent, but Boswell and Humes were present Boyers to HSCA: body tissues processed by 11/24
- Benson to HSCA: more tissue processed on 11/25 Boswell to ARRB: all tissue slides examined by 11/24
- Humes to JAMA: RFK wanted brain buried with body (interment was 11/25)
- Evidence for a later brain exam (c. 12/2/63)
- Finck's written report to Gen. Blumberg notified on 11/29 re, a later exam.
- Finck to ARRB: exam could not have occurred in 2-3 days
- Boyers to HSCA: 6 paraffin blocks, 8 sections processed on 12/2 (brain tissue)
- Clossen typed report closer to 12/2 than to 11/25
- Humes to Specter: all 3 pathologists at brain exam (stated with B&F present)
- Hand written date on final report is 12/6

It should also be noted that Humes initially told the ARRB that the brain examination occurred 1-2 days after 11/22/63 (which seems far too early, since brains usually require 10-14 days to fix in formalin). But, as the deposition proceeded, Humes kept moving the date farther away from 11/22. Home observed that Humes's attitude during this discussion was both defensive and flippant.

Table 2:

- The Appearance of the Brain at the Examinations Appearance at the Earlier Exam (c. 11/25/63)
- Humes to JAMA: 213 of right cerebrum missing Boswell to HSCA: brain too tom up to show a track
- All 3 pathologists saw an entry wound near the EOP (Which would imply cerebellar trauma)
- rays show 30-35 tiny metal particles Appearance at the Later Exam (c. 12/2/63)

- Finck to Blumberg: brain surface looked different from 11/22 Brain mass: 1500 gm. (inconsistent with major tissue loss) Photographs: most of brain present
- Robert Kischner, M.D., to ARRB: brain in photo was fixed for 2 weeks Boyers to HSCA: he saw a bullet track, pre-sagittal laceration described Parasagittal laceration 4-5 cm inferior to vertex, no cerebellar trauma
- Finck's personal notes: no metal fragments
- Humes: he does not note any metal fragments either Table 3: Conflicts in Film and Photographic Techniques Photographic Evidence at the Earlier Exam (c. 11/25/63)
- Stringer to ARRB: photos of sections, including sections on a light box Stringer to ARRB: no views of the inferior (basilar) surface
- Stringer to ARRB (re. B&W): negatives on Kodak portrait pan in duplex holders (no numbers on film)
- Stringer to ARRB (re. color): Kodak Ektachrome positive transparencies
- Photographic Evidence at the Later Exam (c. 12/2/63) Photographs: no sections in official record
- H&B: no sections taken H&F: describe basilar views
- Photographs: basilar views in the official record
- Archives negatives: on Ansco film from a numbered 12-pack Archives films: on Ansco film (with notches), per Stringer

Richard Davis, a neuropathologist at the AFIP, could think of no reason forever omitting brain sections in a gunshot wound case. (He was not asked if a cover-up might be one reason). Boswell told the ARRB the same thing, but could not explain why this fundamental rule had (apparently) been violated in the case of JFK.

Table 4:

- The Skull X-rays vs. the Brain Photographs Skull X-rays (11/22/63)
- Lateral X-ray: black bi-frontal area implies brain missing on both left and right
- Lateral X-ray: black bi-frontal area-implies 114 to 113, at least, of total brain (in addition, more brain is missing from other parts of the X-ray)
- Frontal X-ray: right infra-orbital transverse black band shows only 30% of total brain
- Frontal X-ray: just below this, 80% of the brain is present
- Frontal X-ray: fracture line above left orbit shows only 60-65% of total brain
- Brain Photographs (c. 12/2/63)
- Left-brain intact
- Right brain mostly intact
- Minimal cerebellar trauma

The point of Table 4 is to illustrate the impossible conflicts between the X- rays (taken at the original autopsy) versus the photographs (most likely taken on about Monday, 2 December 1963) of what must be two different brains. These discrepancies, especially in both frontal areas, are otherwise impossible to resolve. The case for conspiracy could be solidly based on this single discrepancy alone.

During his deposition before the ARRB, Humes came very close to revealing the truth about the brain (while viewing a photograph of it), as shown in the following monologue:

Boy, I have trouble with this. I don't know which end is up. What happened here? Looking at this photograph, which is labeled #46, the structure, which is on the right side of the brain, appears to be intact, the cerebrum intact, and that's not right, because it was not. And, and (sic) the structure which is all distorted (pause), let me see (pause), well (pause), well, I guess this; (sic) is the left side of the brain, more or less intact.

The Skull X-Rays

In their autopsy report, the pathologists described the trail of metallic debris as beginning near their proposed entry site (near the EOP) and extending to just above the right eye (Assassination Science 1998, pp. 430-437). The FBI report of Sibert and O'Neill (Warren Commission Document CD-7, reproduced by Josiah Thompson, Six Seconds in Dallas 1967, Appendix G), which they compiled as eyewitnesses at the autopsy, placed the largest metal fragment above the right eye and the next largest at the rear of the skull. The pathologists' report does not provide any detailed description of these metal fragments.

The 6.5 mm "Metal" Object

In 1968, a panel of physicians appointed by then Attorney General Ramsey Clark described, for the first time in history, a 6.5 mm "metal" cross section of a bullet fragment (see Figure 14) that lay at the rear of the skull. I have used quotation marks around the word "metal" because its authenticity is dubious. The evidence for this conclusion has previously been described. [Editor's note: See Assassination Science 1998, pp. 120-137] The evidence for forgery is based upon hundreds of point like measurements of optical density on the X-rays at the National Archives. Optical density is merely a quantitative means of representing the lightness or darkness of a given point on the X-ray film.

The reasons for my conclusion that this object could not have been on the original X-rays, aside from its striking historical absence, were eightfold, as follows.

1. On the lateral X-ray, the transparency of the 6.5 mm object is much less (less light gets through) than for a real 6.5 mm metal slice from an actual Mannlicher-Carcano bullet (as I showed by X-raying a section from such a bullet taped to a real human skull). In other words, a real 6.5 mm piece of metal looks much lighter than the object on the lateral X-ray.
2. On the frontal view, a superposition of images inside this 6.5 mm object can be seen with the naked (myopic) eye; a small hand held magnifying lens works well, too. The original bullet fragment described by Sibert and O'Neill can be seen inside (partially overlapping) the 6.5 mm object. The 6.5 mm object itself is a phantom that

was later introduced in a darkroom laboratory. Such phantom effects have been described in books on special effects in photography, as I discussed in my earlier study (Assassination Science 1998, pp. 120-137).

3. On the frontal X-ray, a transmission scan (taken at intervals of 0.1 mm) of the 6.5 mm object, is entirely consistent with the impression offered by the naked (myopic) eye, most of the metal lies on the right side of the object. (Right and left are oriented with respect to JFK's skull.) It represents the authentic shrapnel described by Sibert and O'Neill.
4. On the lateral X-ray, the transmission measurements (actually OD data) imply more metal at the bottom of this 6.5 mm object than at the center. To the naked eye (see Figure 14), however, on the frontal X-ray a sector at 4 to 6 o'clock is missing, so the data (from the lateral X-ray) should have shown less metal at the bottom. On the frontal X-ray, however, I could actually see with my myopic eyes the original, small piece of shrapnel that was originally located there (described by Sibert and O'Neill). What I saw with my naked eyes was totally consistent with the OD data. The authentic shrapnel was thicker at the bottom than at the top.
5. The teeth are easily visible at the Archives, although they do not appear in any publicly available images. On the frontal X-ray, the 6.5 mm object is very transparent, very definitely lighter (from front to back) than all of the dental amalgams superimposed on one another. This was repeatedly confirmed with OD measurements. This implies that the front-to-back thickness of this 6.5 mm object should be greater than all of the dental amalgams (mercury and silver) stacked on top of one other. In fact, the measurements imply that the front-to-back thickness of this 6.5 mm object should be nearly 10 times larger than it actually is on the lateral X-ray!
6. On the lateral X-ray, the transmission measurements imply that the 6.5 mm object is much thinner (from left to right) than one dental amalgam. This is to be expected since the lateral measurements of transparency provide an authentic estimate of this object while the frontal view has been altered. Furthermore, we already know that the left-to-right thickness of the authentic shrapnel on the original X-ray (as seen with the naked eye and as reported by Sibert and O'Neill) was only 2-3 mm across. All of this data is consistent.
7. On the lateral X-ray, the transmission of this 6.5 mm object and the transmission of the 7 x 2 mm object (above the right eye) are similar, as they should be for fragments of about the same authentic thickness (about 2 mm). This is consistent with the FBI report, but it is wholly inconsistent with the visible (and inauthentic) 6.5 mm object on the frontal view, because the forgers increased its width in the darkroom.
8. On the frontal view, the 6.5 mm object is astonishingly thicker from front to back (by the transmission measurements) than the 7 x 2 mm fragment, even though the naked eye can see (on the lateral X-ray) that they are actually about the same thickness. Again, this is because the forgers widened the 6.5 mm object in the darkroom.

In summary:

1. This evidence is self-consistent
2. It is consistent with Sibert and O'Neill
3. It is consistent with the historical record, from which this 6.5 mm object was totally absent until 1968, five years after the autopsy.

In my prior essay, I described how easy it would have been in 1963 to add a phantom object of this kind to an X-ray. On modern duplicating X-ray film, I also found this rather simple do to in the darkroom. For example, a real scissor was placed over the original X-ray film in the darkroom. The scissors blocked out the light and resulted in a dark image on the copy film. Then shrapnel was added by placing a cardboard template with holes over the first X-ray film. Where the light passed through the holes the image became lighter at the site of the holes on the copy film. In another case, my daughter's plastic template for pterosaur was superimposed in the darkroom over a real skull X-ray film.

Since the publication of my prior essay, Larry Sturdivan, the HSCA ballistics expert, has also stated his unequivocal opinion that this 6.5 mm cross-section cannot possibly represent a piece of metal. In an e-mail conversation with Stuart Wexler, Sturdivan responded as follows (9 March 1998), regarding the 6.5 mm object:

I'm not sure just what that 6.5 mm fragment is. One thing I'm sure it is NOT being a cross-section from the interior of a bullet. I have seen literally thousands of bullets, deformed and undeformed, after penetrating tissue and tissue simulants. Some were bent; some torn in two or more pieces, but to have a cross-section sheared out is physically impossible. That fragment has a lot of mystery associated with it. Some have said it was a piece of the jacket, sheared off by the bone and left on the outside of the skull. I've never seen a perfectly round piece of bullet jacket in any wound. Furthermore, the fragment seems to have greater optical density thin-face on [the frontal X-ray] than it does edgewise [the lateral X-ray]. ...The only thing I can think is that it is an artifact.

The sole purpose of taking X-rays at the autopsy was to locate, and then to remove (for forensic purposes) bullets, or large bullet fragments. That this (apparently largest) object in the X-rays was neither described nor removed at the autopsy has been simply inexplicable. In view of the mysterious absence of this 6.5 mm object from the historical record (until 1968), it would seem inevitable that the pathologists should have clarified this central issue as soon as possible. Nonetheless, the question remained unasked and unresolved, both by the HSCA and then later by JAMA. It was finally asked by the ARRB, when all three pathologists, under oath, finally came face to face with this unique paradox. Their independent answers were at times both astonishing and embarrassing. Excerpts of Boswell and Hume's depositions may be found in Appendix F and Appendix G.

In these new depositions, all three pathologists denied seeing the 6.5 mm object at the autopsy. Boswell and Humes, in particular, were quite emphatic that they had not seen it, and that they had not removed anything of that size. Ebersole's comments to me also

agreed with them. Humes, like Sturdivan, raised the possibility that it may have been an artifact. My response to this is straightforward. Until Humes knew otherwise at the autopsy, it was clearly his responsibility to remove any large object that looked even remotely like a bullet fragment. There is absolutely nothing in the historical record to suggest any discussion about an artifact on the X-ray films during the autopsy. No pathologist nor Ebersole, nor any autopsy personnel has ever suggested or even hinted at such a possibility. Nor has any official investigation ever intimated that this 6.5 mm object might be an artifact. That it was a random artifact (as Sturdivan wants to believe) is most unlikely, after all, the images of the 6.5 mm object are spatially compatible on the two views (the frontal and the lateral). How likely is it that a supposedly random artifact would have agreed in this striking fashion? The only sensible explanation is that it is indeed an artifact, but one intelligently placed at exactly the right site.

This entire subject lies well outside of the official record. If Humes indeed had seen this object on the autopsy X-rays while at the autopsy, even if he thought it was an artifact he was under the greatest obligation to describe and discuss it or, better yet, simply to search that portion of the skull to confirm whether or not a bullet fragment was there. Not finding it, he could then have concluded that it was an artifact. But nothing like this exists in the record: nothing like this ever happened. Sibert and O'Neill describe nothing of this sort in their FBI report, nor does the autopsy report, nor do the pathologists in their ARRB depositions (or in any prior deposition), nor do any other Bethesda witnesses recall any discussion of such an object.

Instead, there is only an eerie silence, exactly what would be expected if this object had been added later (in the darkroom) as I have proposed. In fact, as I have previously explained, this was really quite simple to do. Contemporaneous radiology textbooks (e.g., John B. Cahoon, Jr., *Formulating X-ray Techniques* 1961) contain detailed recipes that were routinely used in that era for the copying of X-ray films. That these led to copies with remarkably good fidelity is also stated in the textbooks of that era, an original and a copy published side by side can be impossible to distinguish, as even the above author noted (p. 42).

The Trail of Metallic Debris on the Lateral X-ray

Humes and Boswell had great trouble with the trail of metallic debris as well (Figure 11). [Editor's note: See the discussion of Smoking Gun #4 in the Prologue.]

In the autopsy report, it is described as extending from the EOP (the entry site for their posterior skull bullet) to a site above the right frontal sinus. Unfortunately for them, the trail of debris lies 10 cm higher at the back of the head, an extraordinary paradox that I have pointed out on numerous occasions (e.g., Letter to the Editor, *Vanity Fair*, February 1995, p. 34), but which neither the HSCA nor JAMA ever seemed curious about. (Cornwell's account is one exception). It is here, more than anywhere else, that Humes has tipped his hand. Shortly before he was asked about this trail in his ARRB testimony, Humes had laid claim to a good memory (supposedly demonstrated by his recall of three late arriving bone fragments). Furthermore, he wrote the autopsy report within 24 hours of the event itself, so that he had no excuse for not recalling this trail correctly. Moreover, it is the only such trail on the X-rays and

necessarily must relate closely to the path of a projectile. There can therefore be no excuse for misallocating this trail, especially by more than half the width of the skull. Finally, Humes was aware of this trail at the autopsy, while simultaneously observing his EOP entry site. These were not sequential events. (See the addenda for the astonishing responses of both Humes and Boswell to questions about this trail.)

Ebersole's role in altering the X-rays is suspicious. He was called to the White House by the Secret Service on Saturday, 23 November (according to Custer, the X-ray technologist). Immediately after this (again according to Custer) that same Saturday morning, Ebersole directed Custer in the taking of X-rays of skull fragments and bullet fragments taped to skull fragments. I believe, like Custer, that these were initial, exploratory steps in the alteration of the autopsy X-rays. Sometime later, most likely within the first month, but probably even earlier, Ebersole, in a bizarre episode involving "Aunt Margaret's skirts" (HSCA Record No. 180-10102-010409), was recalled to the White House to review the skull X-rays. This is when he drew the straight pencil lines on the skull X-rays (that are still there). The cover story for this visit is that his input was being requested for a bust of JFK, unabashedly based upon a skull that was quite thoroughly shattered. Most likely, however, he was simply being monitored for his reaction to the (now altered) X-rays.

It is noteworthy that the Secret Service was involved in this caper, just as they were also involved in the processing and development (and probable alteration) of the autopsy photographs. The chief of the Secret Service, James J. Rowley, apparently was a friend of J. Edgar Hoover and had briefly served in the FBI (under Hoover). Rowley was also the first person to shake LBJ's hand when he stepped off the plane at Andrews Air Force Base. Rowley continued to serve in the Johnson administration, as did both Admiral Burkley and Robert Knudsen, both of whom worked directly out of the White House.

The Burned Drafts

Humes finally admitted to JAMA that he had prepared a diagram at the autopsy, a diagram that never surfaced anywhere. This is in striking agreement with Boswell's comments to Josiah Thompson: "Yes, I'm sure there was another sheet, which had that measurement on it, and which had height, weight [perhaps even the missing fresh brain weight], and some other information. I'm sure of it." (Lifton 1988, Chapter 18.) Humes had also informed JAMA and the HSCA (7HSCA257) that he faithfully copied everything that he had burned in his fireplace; if so, where is this diagram? Humes repeatedly regaled the Warren Commission and the HSCA with his anecdote about burning his autopsy notes: he did not want them to become an object of veneration, as he thought he had seen occur in the case of Lincoln's chair at the Henry Ford Museum in Dearborn, Michigan. In his ARRB deposition of Humes, Jeremy Gunn sets out, with remarkable tenacity, and to Humes's considerable exacerbation, to clarify this record, as follows:

Gunn: How many pages of notes did you take, approximately?

Humes: Oh, I can't tell you now. Maybe two or three... [None of these have ever appeared in any official record.]

Gunn: Have you ever observed that [Boswell's autopsy diagram] appears to have bloodstains on it as well?

Humes: Yes, I do notice it now...

Gunn: Did you ever have any concern about the President's blood being on the document that's now marked Exhibit 1?

Humes: I can't recall, telling you the truth...

Gunn: I'd like to show you the testimony that you offered before the Warren Commission... I'd like you to take a look at pages 372 to the top of 373, and then I'll ask you a question... Mr. Specter asked [a] question... "Answer [by Humes]: In the privacy of my own home, early in the morning of Sunday, November 24, I made a draft of this report, which I later revised and of which this represents the revision. That draft I personally burned in the fireplace of my recreation room."... Does that help refresh your recollection of what was burned in your home?

Humes: Whatever I had, as far as I know, what was burned was everything exclusive of the finished draft that you have...

Gunn: My question [is] whether it was a draft of the report that was burned... or whether it was handwritten notes.

Humes: It was handwritten notes and the first draft that was burned.

Gunn: Do you mean to use the expression "handwritten notes" as being the equivalent of draft of the report?

Humes: I don't know. Again, it's a hair-splitting affair that I can't understand. Everything that I personally prepared until I got to the status of the handwritten document that later was transcribed was destroyed. You can call it anything you want, whether it was the notes or what, I don't know. But whatever I had, I didn't want anything else to remain, period.

Gunn: ...Now, again, the question would be: Did you copy the notes so that you would have a version of the notes without the blood on them but still notes rather than a draft report?

Humes: Yes, precisely. Yes... and from that I made a first draft, and then I destroyed the first draft and the notes. [This is the great admission for the first time in thirty-three years, Humes finally admits to burning more than one item.]

Gunn: So there were, then, two sorts of documents that were burned: one the draft notes, and, two, a draft report?

Humes: Right...

Gunn: Why did you burn the draft report as opposed to the draft notes?

Humes: I don't recall. I don't know. There was no reason... see, we're splitting hairs here, and I'll tell you, it's getting to me a little bit, as you may be able to detect. The only thing I wanted to finish to hand over to whomever, in this case, Admiral Burkley, was my completed version...

Gunn: When I first asked the question, you explained that the reason that you had destroyed it was that it had the blood of the President on it.

Humes: Right...

Gunn: The draft report, of course, would not have had the blood of Humes:

Humes: Well, it may have had errors in spelling or I don't know what was the matter with it, or whether I even ever did that. I don't know. I can't recall. I absolutely can't recall, and I apologize for that. But that's the way the cookie crumbles. I didn't want anything to remain that some squirrel would grab on and make whatever use they might...

Although Humes goes on to insist that the final draft differed in no significant way from the earlier draft, the Sibert and O'Neill report is quite different from the final autopsy report. Their FBI report was based on notes taken at the autopsy; furthermore, these two men had stayed until the official autopsy was over. Most likely, based on their report, JAMA had reported on 4 January 1964 that a bullet had been removed from deep in JFK's right shoulder. [Note again, contrary to Gerald Ford's interference, that the neck was not the site of the wound, even in this early report.] As late as 26 January 1964, The New York Times also reported that a bullet had lodged in JFK's right shoulder. A similar report appeared in The Washington Post of 18 December 1963. The Post reaffirmed its report several years later, on 29 May 1966, even recalling that the initial story had been confirmed with the FBI before publication. The only possible conclusion from all of this is that Humes drastically revised his conclusions after the FBI had left, which was after the autopsy had officially concluded. Humes has always attributed this change to learning (supposedly on Saturday morning, after speaking to Dr. Perry in Dallas) that the tracheotomy had been performed through the bullet wound. However, the autopsy witnesses, who saw a probe pass through the tracheotomy site, leave little doubt that this explanation is disingenuous.

If the first draft did differ from the final version, what items might have changed? There are many possibilities. The first draft may have contained:

1. 'The fresh brain weight'
2. A description of a residual brain so shattered and so small that no possible trail could be seen (quite different from the brain photographs in the Archives), which would hardly have been consistent with a single headshot
3. A description of seriously disrupted cerebellum, which would have corroborated the reports of the Parkland doctors and would have implied a large occipital skull wound (hardly consistent with the photographs that show an intact scalp and the red spot)
4. An accurate description of the trail of metallic debris, going across the top of the skull, where it would have been grossly inconsistent with the much lower occipital entry wound that the pathologists discovered on the inner skull surface.
5. A forthcoming description of the large hole at the rear of the skull, as opposed to the (probably deliberately) imprecise wording of the autopsy report.

6. A description of their attempts to find a bullet path between the back wound and the throat wound (which would obviously have implied knowledge of the bullet wound in the throat)
7. A transit wound, determined by through and through probes (and also by an abrasion collar), that went upward from back to front, in striking disagreement with the SBT
8. A frontal wound in the high, right, forehead/temple near the hairline, where the frontal bullet probably entered (see the section on the frontal headshot).

Since Humes expired in 1999, we will probably never know how these different drafts evolved. In some ways, though, it no longer matters, because so many other clues now exist to the actual state of affairs at the autopsy. Humes's state of mind on that particular weekend is no longer material to the medical evidence, although I shall comment below on the pathologists' behavior, insofar as it affords liberty for speculation on their impact on other medical aspects of the case.

The Autopsy Protocol: Is It Authentic?

Is the current autopsy protocol (CE-387) the same as the one that was signed on Sunday, November 24? Although at first sight this question seems radical, it has previously been discussed by Lifton (1988, chapters 17 and 18) and was again raised by Douglas P. Horne at the ARRB ("Chain-of-Custody Discrepancy Regarding Original Copy of JFK Autopsy Protocol, 2 August 1996). Lifton had obtained, under the Freedom of Information Act, a Secret Service memorandum (dated 12 February 1969) of a meeting that included Secret Service Inspector Kelley. As Harry R. Van Cleve, Jr., of the General Services Administration explained, although the Secret Service had transferred autopsy items 1 through 9 to the Kennedy family on 26 April 1965, they, in turn, had not transferred all of these items to the Archives. In particular, important autopsy materials from 9 were missing; this had been discovered on 29 October 1966, at the time of the original donation. These items included tissue slides and a stainless steel container (most likely a brain). But Kelley noted yet another problem: item 9 had also included the original autopsy protocol and seven copies! These, too, were gone. But the problem was even stranger than this: on 3 October 1967 (the following year) the Secret Service sent the (supposed) original autopsy protocol to the Archives! Even more interesting was that James J. Rowley, Chief of the Secret Service, signed out this transfer. Horne even discovered a receipt dated the next day, which was signed for by an Archives official named Simmons. As Kelley wrote: "This could raise the question about two original autopsy protocols. We, of course, were unable to resolve this discrepancy since we do not have access to the paper referred to in Dr. Burkley's inventory. We can speculate..." As Lifton concludes, this matter was never resolved.

Horne's memo notes several other serious problems. The (supposed) original protocol transferred by the Burkley inventory reads: "...An original signed by Dr. Humes, pathologist." 'However the extant protocol' (CE-387 see Assassination Science 1998, pp. 430-437) is signed by all three pathologists. Horne adds that this apparent discrepancy is especially peculiar because the inventory is, in all respects, quite

precise. (Author's note: these problems are thoroughly confounded by the absence of a typewritten date on both the extant autopsy protocol and on the supplementary examination of the brain. Were these omissions deliberate?)

Horne then lists one of the great lingering mysteries about the medical evidence, a transcript from an Executive Session of the Warren Commission (27 January 1964), quoting J. Lee Rankin, the Chief Counsel:

We have an explanation there in the autopsy that probably a fragment came out the front of the neck, but with the elevation the shot must have come from, and the angle, it seems quite apparent now, since we have the picture of where the bullet entered in the back, that the bullet entered below the shoulder blade to the right of the backbone, which is below the place where the picture shows the bullet came out in the neck band of the shirt in front, and the bullet, according to the autopsy didn't strike any bone at all... (Weisberg 1975, p. 307.)

Since no known version of an autopsy report not CE-387, nor the Sibert and O'Neill report, nor any subsequent FBI report describes a bullet emerging from the throat, this is a completely inexplicable mystery, still unresolved to this very day.

Horne also notes that Burkley's death certificate, completed on 23 November 1963 (Saturday), describes the back wound at the level of T3. It seems unlikely that Burkley, without consultation, would have reached such a detailed anatomic conclusion. The obvious question is: did Burkley obtain this from an earlier version of the autopsy protocol, one that has since vanished?

Horne adds that an FBI summary report (9 December 1963) concluded that a bullet had lodged in JFK's back. This may have served as the source for the various media (and JAMA) reports with the same information. The extant protocol (CE-387) was not formally transmitted to the FBI until 23

December 1963. Therefore, there was time for changes in the protocol of which the FBI might have remained ignorant.

Horne believes it likely that the autopsy protocol was revised between 24 November and 11 December 1963. This would explain:

1. The media reports of a bullet in the back.
2. The FBI reports, including that of Sibert and O'Neill that differed from the extant protocol.
3. The strange content of the extant protocol.
4. The appearance, probably on 11 December, of Secret Service agents (including Elmer Moore) at Parkland Hospital.

Their apparent purpose was to show the (extant) protocol to the Parkland physicians, to get them to agree to the official story. Horne also notes that the viewing of the Zapruder film in this critical interval may have raised insoluble timing problems: the throat wound clearly could not have occurred at the same time as the headshot. Horne concludes with one strange fact: the first known media report of a transiting bullet (one

that exited the throat) appeared in the Dallas Times-Herald on 12 December 1963, just one day after the Secret Service visit to Dallas!

For this scenario to work, Horne notes that the original protocol (presumably dated November 24) had to be suppressed, and then later replaced by one written shortly afterward. He speculates that this substitution could have occurred during the transfer from Burkley/Secret Service to the Kennedy family in April 1965. The Navy letters of transmittal (24 November) and the receipts (24 and 25 November) could have remained in place even though the autopsy protocol was no longer the same. Only Burkley and a few Secret Service officials need have been privy to this deception.

Horne notes that Humes and Boswell persistently claimed that there was only one autopsy protocol and Humes claimed that it was signed on Sunday, November 24. If the above arguments are correct, however, then both Humes and Boswell have committed perjury.

The remaining mystery is how Rankin saw a copy of the earlier protocol. Careful reading of the transcript does not prove that Rankin actually held such a copy in his hands at that moment. Perhaps, by accident, he had seen one of the copies of the original. What is known is that the extant protocol (CE-387) was transmitted by the Secret Service to the Warren Commission on 20 December 1963. Therefore, since the Commission already had this protocol on 27 January 1964 (the date of the Executive Session), another mystery is why Rankin was not quoting from it rather than from some other version.

The following items are also suspicious:

1. None of the seven copies exists today
2. Humes's handwritten protocol (Weisberg 1975, pp. 509-523) does not contain a date.
3. The extant protocol was not publicly available until it appeared in The Warren Report.
4. Boswell's diagram did not appear in The Warren Report.
5. The Sibert and O'Neill report was omitted from The Warren Report.

Rankin's quote raises another question: was the back wound truly below the shoulder blade? Rankin specifically refers to a "picture" as his reason for so describing it. If it were that low, it would be consistent with the above discussion of a wound at T3 (Berkley's death certificate) or T4 (Ebersole's description to me). Such a low site would also be consistent with other evidence (Assassination Science 1998, pp. 110-111), most especially with the holes in the coat and shirt. If that were the true location, it would mean that the photograph of the back (Figure 2) was altered to elevate the wound, but it would also suggest that Rankin himself was complicit in later accepting the SBT in face of a back wound that he knew was too low (as he himself stated in the above quote).

The role of Admiral George Gregory Burkley in all of this is most curious. Although initially he was quite emphatic that there had been no conspiracy, in 1982 he told Henry

Hurt (Reasonable Doubt 1985, p. 49) that he did believe in a conspiracy. He had previously admitted similar sentiments on tape (Oral History, JFK Library, 17 October 1967); when asked about the number of bullets that had entered JFK's body, he responded: "I would not care to be quoted on that." Burkley's attorney, William F. Illig, also told Chief Counsel Richard A. Sprague (Palamara 1998, p. 46) that Burkley had entertained the possibility of conspiracy. According to Illig, Burkley did not even rule out the possibility of two headshots. It is curious, but true, that Burkley did not testify before the Warren Commission, despite the fact that he was the only individual present at both Parkland and at Bethesda. When David Lifton tried to interview him, he refused to cooperate (Lifton 1988, pp. 401-402). James Folliard ("Blaming the Victims: Kennedy Family Control over the Bethesda Autopsy," *The Fourth Decade*, May 1995, p. 5) extensively explored Burkley's role at the autopsy. According to *The New York Times* (11 January 1969), Burkley remained LBJ's personal physician

from 12:30 PM, 22 November 1963 until January 1969, when Johnson retired. If I could choose one witness to depose under oath, it would be George Burkley. Unfortunately, Burkley died before the ARRB legislation was passed, thus leaving many interesting questions unasked. His daughter Nancy Denlea, refused to donate his personal papers to the ARRB.

Altered Photographs: How Was It Done?

[Authors note: Although this section is necessarily speculative, what I propose here seems the simplest explanation for the current evidence. Nonetheless, new evidence could modify this proposal, which reflects the fallibility of scientific reasoning.]

The images that Spencer saw are a key to the puzzle. There are too many odd features in her recollection, the photo collection was too limited, the images were on color negatives (instead of on transparencies), and the wrong lab was used. The central clue lies in the nature of the images: they are almost bloodless, which is oddly similar to the extant views of the back of the head. Spencer's activity at the Anacostia lab was probably an intermediate step in the alteration process. Although at least one photograph showed JFK's face, this view might have been included merely to misdirect Spencer into believing that the entire set of photographs that she saw was authentic.

The fact that they were on color negatives is *prima facie* proof that they were not originals. That Spencer saw autopsy photographs only once is also evidence that this entire operation (of film alteration, in my view) was compartmentalized. As further evidence, Knudsen and Fox both recall that they traveled more than once to Anacostia, on errands with these photographs, while Spencer, by her own testimony was involved only once. Furthermore, Spencer's recollection of the date of her work differs from that of Knudsen and Fox.

An additional clue is the presence of a small throat wound, only about half an inch across (according to Spencer). This image can only be of someone else's throat or possibly a photographic alteration of an original autopsy photograph. But why would this have been included in the set at all?

If the tracheotomy had been altered (e.g., in a search for a bullet), then the inclusion of a small throat wound in the set (perhaps designed to mimic the throat wound in Dallas)

would have permitted the subsequent photographic restoration of the throat wound to its Parkland Hospital status. That this

was ultimately not done, of course, is a separate issue; perhaps the forgers decided that such a transformation was too risky, especially since so many individuals had seen a much larger, and much more irregular, wound at the autopsy (Figure 15).

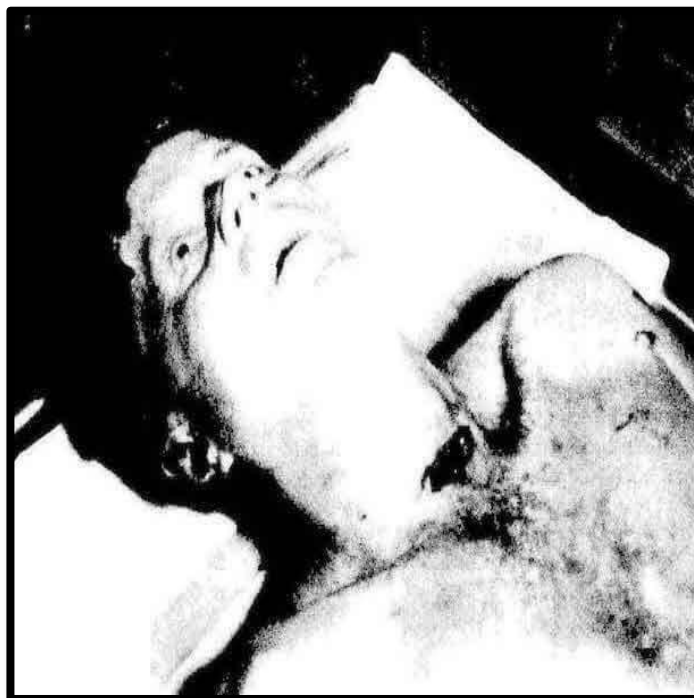

Figure 15. Photograph of the Throat Wound Malcolm Perry, who performed the tracheotomy, was never asked to demonstrate his technique by submitting a photographic collection of his own work.

What were the prior and subsequent steps in this process and where did they occur? Although this cannot be answered with certainty, the preparation of composite photographs may have involved processes such as soft matte insertions (Grodin 1993, p. 85). The existence of color negatives (as seen by Spencer) is proof that the original color transparencies had already been re-photographed, probably with a view to forming composites as the next step. Spencer may also have seen photographs of another body, as suggested by the small tracheotomy wound.

Although an image of someone else's hair could have been used to cover the large hole in the posterior head, another possibility is the use of (the image of) the left side of JFK's own posterior scalp (by turning the negative over in a double exposure), so as to cover the wound on the right, assuming that an appropriate image existed in the original collection. Once these composite photographs were deemed satisfactory, then the images had to be converted, once again, to color transparency format, which is what currently exists in the Archives. No existing evidence pinpoints where this work was done, other than the frequent visits to the NPC.

An official statement (HSCA Record# 180-10109-10368), signed in February 1967 (three years and three months after the event) by Roy Kellerman, Robert Bouck, Edith Duncan, James K. Fox, and Thomas Kelly, attempts to reconstruct the

whereabouts of the autopsy films. Bouck gave the films to 'Fox on November 27 (Wednesday) and then Fox took them to NPC that same day. B&W negatives were developed, and color positives were made from the colored film. Color transparencies are not mentioned. Lt. V Madonia did the processing and development. Fox then returned these materials to Bouck at about 2:30 P.M. the same day. Several days later, Fox made B&W prints at the SS lab (in the Old Executive Office Building, which could only handle B&W). On about December 9 (Monday), Fox took the color positives to NPC and made color prints. These were returned to Bouck by 6 P.M. the same day.

What is curious about this sequence is that both Spencer and Knudsen are missing and that Spencer did not see autopsy photographs on any of the cited dates. Furthermore, Spencer handled color negatives, not transparencies. In addition, Madonia had independently claimed he could not have done this work since he was the supervisor and his laboratory skills had atrophied. So what can be concluded? Most likely, the procedures followed were more complex than most participants recognized, or perhaps memories had faded in the rather long interval. Nonetheless, one person is present in all of these stories; it is James K. Fox, the Secret Service photographer. It is likely that (under Bouck's direction) he played the major role, at least as a liaison. Whether he actually constructed composite photographs, however, we cannot determine based on the available evidence.

It is likely, however (since he processed JFK films, probably on several occasions), that he understood the whole sequence of events. If Fox knew, then Bouck (his immediate superior) and James J. Rowley (Chief of the Secret Service) should also have known. Beyond that it is impossible to see with any clarity into the hierarchy. (Rowley's superior was the Secretary of the Treasury, Douglas Dillon.)

The witnesses tell us that the NPC could have handled all of the photographic formats discussed. We do not know, however, whether work was done at some other government lab (possibly motivated by the enhanced secrecy offered by compartmentalization). The Knudsen family does recall occasional encounters with other government photographers. Although it is likely that the secretive NSA had extensive photographic facilities at that time, there is no evidence to suggest their involvement. On the other hand, both James Fetzer and I have received anonymous letters claiming that the AFIP was involved, but this has never been pursued. At the present time, nothing in the record indicates that the films went anywhere but the NPC and the Secret Service laboratory (in the Executive Office Building). In fact, in an ARRB interview, Velma Reumann (Vogler) recalled:

...A strong, independent recollection of NPC personnel boxing up all photographic materials... related to the assassination on the orders of Robert Kennedy and sending them to the Smithsonian Museum for permanent storage sometime within 6 months or so after the assassination...

...She said she was certain of this because she, herself, was required to call an official at the Smithsonian to discuss the imminent transfer, and recalls the individual to whom she spoke was as surprised by the selection of the Smithsonian as she was. (Also see Livingstone 1998, pp. 441-442.)

Any list of prime suspects (whether witting or unwitting) for the alteration of the photographs must include Robert Knudsen. He told his family (who apparently believed him) that he had photographed the autopsy, a story that was almost certainly false, in any literal interpretation, because no one recalls his presence at the autopsy. Why he found it necessary to recount this misleading story to his family (and to maintain it until death) is curious, but it is also a clue particularly since one personal trait that his wife voluntarily recalled was his honesty. She also recalled that he was quite reliable about keeping secrets, voluntarily adding that sometimes military people must "take secrets to the grave" with them, especially when ordered to do so. It should be noted that Knudsen implied to the HSCA that he first encountered the photographs on the morning after the assassination, when Burkley handed them over in a paper bag. But even though he was quite certainly not at the autopsy, Knudsen also recalled that he had been up all night! Was Knudsen already working with the photographs, perhaps even during the autopsy, thus lending some truth to the story that he told his family? Curiously, the Associated Press ran a story (31 July 1998) by Deb Reichmann:

New testimony released Friday about the autopsy on John F. Kennedy says a second set of pictures (sic) taken of Kennedy's wounds pictures never made public. The existence of additional photographs believed taken by Robert L. Knudsen during or after the autopsy... raised new questions... But the new evidence sheds no light on the whereabouts of the second set of pictures.

George Lardner (The Washington Post, 2 August 1998) also reported on photographs 'believed to have been taken' at Bethesda, by Robert Knudsen. Perhaps Knudsen did photograph the autopsy, after all, by the indirect process of taking pictures of autopsy pictures. This, by itself though, would be an odd state of affairs, which no investigation ever addressed. Within a few days of the assassination, according to Joe O'Donnell (Knudsen's colleague), Knudsen showed him photographs that first showed a hole at the right rear of the head, and then, several days later in a similar view, the hole was gone. This disclosure by Knudsen inevitably suggests some knowledge of abnormal activities; furthermore, given the unavoidable compartmentalization of such nefarious behavior (assuming that it actually occurred), Knudsen's knowledge of it is striking. Either he, or someone very close to him, had to be involved.

Given his ability to keep a secret (according to his wife), it is difficult to believe that he would have chosen this moment to give away someone else's secret, especially for such a highly covert project. More likely, he himself had performed, or had assisted in, these very alterations. As the White House photographer, Knudsen clearly possessed darkroom skills in his own HSCA testimony he recounts processing films at Anacostia during the initial weekend. Furthermore, his position as White House photographer had two important advantages for conspirators:

1. His subsequent loyalty (and silence) could easily be monitored by powerful figures close to the White House.
2. He had access to, and often used, the White House section of the secretive Naval Photographic Center at Anacostia.

Was Knudsen asked to re-photograph the autopsy photographs, perhaps after being given a cover story, one that he either believed, or decided that he must accept (e.g.,

perhaps that the Kennedy family needed a sanitized version of the autopsy)? If so, he might even have claimed some innocence in the matter, particularly if he did not know how the photographs would later be used. Perhaps guilt and exasperation, which were recalled by his wife, later emerged at the 1988 hearing, as he became fully aware of how his own work had contributed to the cover-up. The only other known candidates for an alteration role are James K. Fox (Secret Service photographer) and Vincent Madonia (supervisor of the NPC color laboratory). Knudsen's possession of original and altered photographs within the first week, his curious busyness during the first night, and his own self-admitted hectic schedule, provide some corroboration for such illicit activity. When his subsequent, official appearance in 1988 and the earlier burglary at his home (shortly after his HSCA deposition) are added to the riddle, his own participation becomes even more suspect. That he never confessed to his family that he had really not photographed the autopsy only adds to the suspicious character of his story.

In his own interview, Madonia also recalled being extremely busy for the first three days (precisely the time interval described by Knudsen), beginning, strangely enough, the very evening of the autopsy. He also recalled additional, smaller projects over the succeeding days. Although Knudsen described Madonia's personal processing and development of some of the autopsy photographs on one occasion, Madonia implied that he (Madonia) was primarily a supervisor during these busy days and that he probably could not even have functioned well in the darkroom. If true, he would be left mostly outside the net of conspiracy. (I have listened to his deposition on audiotapes and that is my impression from the tapes as well.)

Knudsen also recalled for the HSCA that he saw photographs that showed probes in JFK's back. But if he was not at the autopsy, how could he have seen such probes, unless he saw photographs with probes? And if he saw such photographs, why were they made available to him, particularly since he played no official role in the autopsy? Why was his presence necessary at all when he and Fox took the duplex holders to Anacostia? Wasn't one courier enough on such a busy weekend? Given the corroboration of such probes by many witnesses Karnei, O'Donnell, Sibert, O'Neill, autopsy technicians, and others, it is likely that Knudsen did see such probes. If so, these photographs have disappeared. Moreover, if his recall of the probes were wrong, why would so many other witnesses all invent the same old story of seeing such probes?

Douglas Horne was present when Kodak digitized the autopsy photographs for the ARRB in Rochester, NY. He recalls that a careful examination of the posterior head photographs was made, with the specific purpose of identifying matte insert lines or any other evidence of photographic alteration, but no evidence was seen. However, a complete re-photographing of all autopsy photographs could make it difficult to detect such alteration. Perhaps this task was what kept Knudsen so busy, particularly if composite photographs had to be made. The fact that multiple trips to Anacostia did occur, over several days, is consistent with such a step-by-step process, perhaps even requiring several revisions until the end product was satisfactory, and then, finally, re-shooting the entire set.

An additional possibility is that some negatives were deliberately turned over in the dark room during the preparation of prints. (Liz Snyder first proposed this possibility

to me in February 2000, in Monterey, California.) This process would have reversed left for right. For example, if an intact, left, rear scalp had existed in the original collection, and then such manipulation might have restored the right scalp. Furthermore, if the left back had been substituted for the right back (Figure 3), then a fake wound could more easily have been superimposed onto the back. Figure 3 does display several odd features:

1. The ruler is not aligned with the spine.
2. Although the letters and number are not reversed on the ruler, a drug (Tuinal) is advertised.
3. The pair of hands on the ruler cannot belong to the same person (the right hand is on top and the left hand is on the bottom)
4. The hand on the top of the right shoulder is a right hand (rather than the expected left hand)
5. There is a small dark area adjacent to the fourth finger of the left hand.
6. Across the midline from this latter site, almost at the mirror image site, is another dark area.
7. The site of the wound, based on the pathologists' actual measurements, has previously been displayed on this same photograph (Assassination Science 1998, p. 444 see the circled X). Also see nurse Diana Bowren's location of the back wound in Livingstone (1993, photograph opposite p. 368).

This photograph raises numerous questions, as follows:

1. Were parts of this image reversed?
2. Why is a Bethesda ruler not being used (the Bethesda medical personnel have suggested that it was)?
3. Was the real wound located near the left fourth finger or possibly even at the mirror image site on the right?
4. Was the ruler (and perhaps also the hands) later added to the photograph?
5. What actual purpose is served by, the ruler in its present odd location?
6. Is the wound in the photograph really as far as 5 cm from the midline (as officially reported)?

[Authors note: James Thornton, M.D., a surgeon, has recently begun exploring the possibility that some photographs have been partly or completely reversed. It is curious that no one heretofore has examined this possibility.]

The autopsy camera is yet another unexpected paradox. The HSCA concluded that the only camera that the Navy could produce for the HSCA investigation, a camera that the Navy, in fact, considered to be the actual autopsy camera could not have been used for taking the extant autopsy photographs! [Editor's note: Gary Aguilar, M.D., elsewhere

in this volume, discusses this point.] Consider, however, that if all of the photographs had been re-shot, it would explain not one, but two, mysteries:

1. Why the photographs do not match the camera (they may have matched a different camera, possibly the Nikon used by Knudsen, an issue no one ever explored)
2. Why photographic alteration has been so difficult to detect.

If 'Knudsen had participated in this affair, who would have issued his orders? In his HSCA interview, he recalled following orders issued by Admiral Burkley, who, like Knudsen, was a Navy man. Several autopsy witnesses describe Burkley as controlling the autopsy itself. In oral interviews at the JFK Library in Boston, Burkley agreed that this was his role. If true, might he also have played a role in the alteration of the autopsy photographs? Since he was JFK's personal physician that weekend (Kathleen Cunningham, however, has noted that Janet Travell was listed as the official White House physician), since he had completed a death certificate for JFK, and because he was the only individual present both at Parkland and at Bethesda, his unaccountable absence from the Warren Commission remains quite inexplicable.

The recent interviews and releases by the ARRB have thoroughly altered our view of the medical evidence. It is no longer good enough merely to point to the back of the head photograph and conclude (as prior official reviews have done) that the headshot came from the rear and that the posterior skull was intact. Let us be honest about this: medical experts are not even required. Even the man in the street can guess that this red spot is supposed to be a wound, and probably even a wound of entry! But there has always been a problem with this convenient solution to the crime of the century; the three pathologists have persistently disagreed with this conclusion. Not only have they disagreed, but also they have disagreed vigorously. I suspect that they were right, that a bullet really did enter at the EOP, but that it was not the only headshot. In conclusion, with the introduction of the new witness's suspicions about the accuracy, and even the authenticity, of the posterior head photographs have deepened considerably.

The Harper Bone Fragment 22

At 5:30 P.M. Saturday, November 23, a pre-med student, Billy Harper, found a fragment of skull bone (7HSCA123-124) on the grass south of Elm Street, not too far from where Jean Hill had been standing. (The exact site is not well defined, however.) Harper took it to his uncle, Jack C. Harper, M.D., who in turn showed it to A.B. Cairns, the chief pathologist at Methodist Hospital. A total of three Dallas pathologists examined the bone and they identified the site of origin as the occiput. (On 22 November 1992, on a Palm Springs radio talk show, I helped to interview one of these pathologists, Dr. Gerhard Noteboom, who reaffirmed that conclusion; he also recalled the lead deposit on the fragment.) The bone was then shipped to Admiral Burkley, who, in turn, gave it to the FBI, where it was lost. Fortunately, photographs were taken in Dallas (Figure 2A and Figure 2B). A ruler on the photograph permits an estimate of size: it is about 7 x 5.5 cm, and trapezoidal in shape.

Joe Riley, Ph.D., a neuroanatomist (formerly in academia), places this bone into the parietal area (Joe Riley, "Anatomy of the Harper Fragment," JFK Deep Politics Quarterly, April 1996). Riley and I have exchanged many (mostly e-mail) comments about this fragment. Although we succeeded modestly in reducing our disagreements, nonetheless, we still remained far apart, with Riley continuing to favor a parietal origin, while I favored an occipital origin. Having great respect for Riley's expertise, I put this question aside for several years. But, as I continued to review the X-rays, the mystery photograph F8 (the Postscript), the statements of the Dallas pathologists and the Bethesda pathologists, and the fragment itself, I remained convinced that it was (mostly) of occipital origin. I believe that Riley has overlooked much valuable evidence, and that his objections can be effectively countered. The employment of the X-rays and the proper orientation of F8 are a powerful combination that should not be overlooked, especially when coupled with information on the bone itself.

If I understand him correctly, Riley has primarily argued that the Harper fragment cannot be from the low occiput, as Groden shows it (1993, p. 83). In fact, I agree with Riley on this point because the fragment is actually (mostly) from the high occiput, but it includes a small portion of adjacent parietal bone as well, on both sides of midline. The exterior surface appears to show the junction of three suture lines. If this is true (Riley does not agree), then this bone should be fairly easy to place: there are few skull sites with such a trifurcate junction. One of them is the lambda point, the junction of the parietal and occipital bones, right at midline. Now it seemed to me that the shortest of these lines (the one going straight up to the top edge in the photograph) was the midsagittal suture, and the two lines going off to either side of these were the lambdoid sutures. But Riley argued that one of these was a fracture line, not a suture line, an issue that simply cannot be resolved with finality from a 2D image. I argued, however, that it was odd that such a fracture line was not apparent on the inside of the bone. Furthermore, it seemed to me that the supposed fracture line contained too many fine twists and turns. It looked much more like a suture line, unlike other real fracture lines that I could see on the X-rays or, for that matter, on the edge of the Harper fragment itself.

I had thought that Riley's fracture line was supposed to lie between sections F and G in Figure 2A, because it contained the smallest number of fine twists and turns. However, I was stunned when I saw that J. Lawrence Angel, Curator of Physical Anthropology at the Smithsonian, who was consulted by the HSCA about its significance, had totally ignored the line between sections E and F (without any explanation), which assuredly contains many tight curves, as one would expect for an authentic suture line. But then I realized why Angel had made this mistake. The faulty 'HSCA diagram' had probably misled him. (Figure 7) that showed no hole at the back of the skull. Since he had already placed the large, late arriving fragment anterior to the coronal suture (which may be correct), he had only one other site left, the gap in the parietal bone, which is where he put it.

The entire bone segment 'F' (the upper right portion of the fragment as viewed from the exterior) appears whiter because it has little blood on it, whereas the two adjacent segments are bloodstained. It would appear that suture lines act as a barrier to the spreading of blood. I accidentally discovered evidence for this; when I was doing

skull experiments with simulated brain material, I noticed that the dye in this material leaked from the inside of the skull to the outside, right along the suture lines, but only along such lines. In other words, these suture lines acted like miniature sinks, thus stopping blood from crossing over. An explanation therefore exists for why segment F might have remained unstained.

Both Angel and Riley argued for a parietal site based on the vascular grooves (curvilinear indentations) and the foramina (perforating holes for small vessels) on the inside surface. But I found it easy to demonstrate exactly these same features in the upper occipital bone on two genuine human skulls that I owned, and I could easily see them in multiple anatomy textbooks, extending over many decades, so I did not consider these arguments to be decisive. Moreover, the direction of the vascular grooves, although consistent with a parietal site, was also surprisingly consistent with an upper occipital site, which was also not hard to demonstrate. I could easily see these on my skulls (the grooves did go in the right direction) and it was not hard to find photographs in texts that were equally supportive. (I doubt that Angel ever did this exercise, since he automatically ruled out the back of the head, nor do I really know if Riley performed this exercise for the upper occiput, since he seemed so focused on the lower occiput.)

When I examined the triangular area of missing bone (see the small white triangle in the figure in the Postscript), near the low midline, on photo F8, I remembered that I had seen this empty triangle before on the X-rays. (Although I did not mention it in the Postscript, this argument, too, helped to persuade me of the correct orientation of F8.) I already knew, from naked eye viewing (with very myopic eyes, the best kind for the job) and from detailed OD measurements, that bone was absent in just this same triangular area on the frontal X-ray (approximately inside the lower left nose). I had not gone looking for this; I merely happened one day to notice it while at the Archives. Since no one had reported such missing bone from the left side of the skull, I was surprised and decided to explore it further with more OD measurements. Since I now knew the orientation of F8 and its dimensions (there is a ruler on F8) and because I could correlate identical objects on F8 with the photographs and because I already knew the dimensions on the skull (from my own measurements at the Archives), I could now estimate the size of this empty triangle on F8.

It was probably sometime later, however, when I returned to this jigsaw puzzle, trying to imagine where the Harper fragment might fit into the skull. When I did, I realized that its left edge (on the exterior view) might fit into the empty triangle. In fact, it seemed to fit extremely well, so I proceeded to the other borders. In particular, I wanted to know how far it would extend towards the right, because the pathologists had placed their entry hole to the right of midline. As I measured this distance on F8 and compared it to

the well-defined distance along the bottom edge of the Harper fragment, I realized that the right edge of the Harper fragment lay very close to the pathologists' EOP entry hole. But then it really hit me: after all of this, I had quite unexpectedly placed the lead debris (on the Harper fragment, described by the Dallas pathologists as possibly from a bullet, and still visible in the photograph) almost exactly where the pathologists had said the bullet had entered. I stared, almost too shocked to believe it. I returned to the X-rays looking for possible contradictions and found none. I reviewed all of the

borders, to be sure that the X-rays permitted such a placement and they did! In addition, the lambdoid sutures, one on each side of the skull, as examined on both the lateral and frontal X-rays, are also remarkably consistent with this interpretation.

The Harper fragment (H) is shown situated in the occiput in Figure 2C. Letters C and D identify bone fragments. Letter L denotes the site of lead on H. The 6.5 mm object is shown at about the 2 o'clock direction from the right upper edge of H; it also lies directly inferior to the letter D. The letters McC (for McClelland) identify the fracture that functioned as a hinge for a bone flap that could swing either open or closed. This movement has been the cause of much confusion about the status of the occiput: when the flap was open (as at Parkland) it produced an orange sized hole at the right rear, but when closed (as on the frontal X-ray) it seemed that there was no major hole at the right rear. I have named this hinge after McClelland, who actually described the bone flap. This fracture is also visible on the frontal X-ray. The area inferior to this flap is not well seen on the X-rays (it is obscured by overlying bone), but the OD measurements suggest that some bone is missing below this flap. This would be consistent with the eyewitnesses' recall of an orange-sized hole at this site. The semicircular notch, located on line BA and just inferior to letter C, is where Baden placed the exit wound.

The Harper fragment (H) is placed into the frontal skull X-ray in Figure 2D. In this figure the lambda point (the junction of the two lambdoid sutures and the sagittal suture) lies slightly inferior to the top of the Harper fragment. Most of the lambdoid sutures can be seen on the frontal and lateral X-rays, at sites that are consistent with this interpretation. Furthermore, where these sutures are missing is exactly where the Harper fragment (not present at the autopsy) fits into the skull. Optical density measurements confirm that bone is indeed missing where the Harper fragment has been placed here. Baden's semicircular notch is not visible here, but must lie between bone fragment C and the top of the Harper fragment. The letter L denotes lead on the Harper fragment. Regarding Baden's notch, Roger McCarthy of Failure Analysis Associates has shown that beveling can occur from a gunshot even without an exit or an entrance wound as the direct cause (Livingstone 1995, p. 313).

This is the simplest, and the most complete, integration of all of the known evidence. Furthermore, after looking at genuine human skulls and textbooks, I see no real problem with the evidence on the bone itself, from either the inside or the outside. Finally, though, I would emphasize that, like the certainty of the three autopsy pathologists about the site of the entry wound, we should also take seriously the word of three Dallas pathologists who actually saw the real 3D bone. They all agreed that it was occipital, which is probably the best evidence we shall ever get on this question. I have merely found the only reasonable place at the back of the skull where it could possibly fit. Such a conclusion is, incidentally, yet one more proof that bone was indeed missing from the back of the head, as if more proof were really required on this point.

Neutron Activation Analysis (NAA)

Having once taught a course in nuclear physics (1971-72) while on the Michigan physics faculty I was naturally captivated by the statement that NAA had confirmed the SBT. I had even watched Robert Blakey declare on national television that NAA was the

lynchpin of the SBT theory, for anyone who had the wherewithal to understand it. Since I thought that such a statement might include me, I determined to look into it. Several months later, when I finally obtained access to the NAA data in the HSCA volumes (at U.C. San Diego, while on vacation), I was surprised, on even a first reading, at how unconvincing it seemed.

This was a critical moment for me, a time when the lone assassin theory began to disintegrate; if a supposedly final, and indisputable, proof, from nuclear physics was so feeble, I could only imagine that other proofs of the lone assassin theory would be even more unreliable. Later, I had the pleasure of reading a detailed critique by Wallace Milam, which only further undermined the NAA evidence. More recently, a Stanford physicist, Art Snyder, Ph.D., has been exploring the statistics of NAA for these metal fragments in further detail. Just several months ago, I listened with gratification as Snyder explained his arguments in a lecture. By all reasonable measures, based first on the work of Milam, and now on the work of Snyder, the NAA does not support the SBT. Nor does it support conspiracy though: it is simply inconclusive, actually almost useless. I am hopeful that Snyder will eventually publish his work so that Blakey can explain his "lynchpin" one more time for us.

The Behavior of the Pathologists

The bedrock of the case against the pathologists is the trail of metallic debris, especially as seen on the lateral X-ray. This trail, lying high on the skull, must surely be related to a projectile passing nearby. Its great distance (actually more than 10 cm) from the pathologists' entry site (near the EOP) is impossible to reconcile with a single shot at the EOP. Since the pathologists saw this trail at the autopsy, while they simultaneously identified an EOP entry, they must have known, and understood all too well, exactly what it meant, a second shot to the head. Writing the official autopsy report within 24 hours, Humes certainly knew well enough where this trail lay, specifically that it laid nowhere near his EOP entry site. This is not a matter of professional competence or training, it requires only an elementary education, at best. I know for certain (because I tested him) that my now ninth grade son (who hopes someday to become a forensic scientist), given the information about the bullet trail and the EOP entry site, could have done better than this: he quickly recognized that this data set implied a second shot.

This was the moment of truth for James J. Humes. He could have described the trail correctly, which would always thereafter have invited the question of a second headshot (using exactly the argument that Cornwell had invoked). But he chose instead to follow the clear directions that he had received as the autopsy began (the sole gunman had shot from the rear and was already in custody). Because he chose to support the lone gunman theory, he had no choice but to displace this trail downwards by a huge distance. Because he did not have to review the autopsy X-rays, or even the photographs, for the Warren Commission, no questions were asked at that time about his dangerous maneuver.

When he next saw the X-rays, with the Clark Panel in 1967, he must surely have seen the curious 6.5 mm object (for the first time) and he was probably immediately suspicious. His comments were not recorded during this panel, however, but an official opportunity arose with the HSCA. Here, however, despite several opportunities to describe the

unanticipated materialization of this object, he made no attempt to do so. Instead, he chose to agree with Cornwell that he had made a grievous error, an apology that he totally ignored when he next had a chance during his JAMA interview.

The photographs of the posterior skull also offered an opportunity to raise questions of authenticity, particularly with respect to the red spot. Moreover, in excerpts from his ARRB testimony (included here) Humes actually stated that, even after all reconstruction attempts, the scalp remained open for several centimeters. Yet, even the briefest glance at Figure 1 reveals the paradox: the scalp is completely closed and the hair is all well-manicured, not at all open by the several centimeters that Humes recalled. Humes was not directly asked to explain this obvious discrepancy, but he must surely have been aware of it.

The brain weight is yet another paradox. Standard textbooks give the upper limit of normal for the adult male brain at about 1400 grams. (I understand that Oliver Cromwell's was much larger, but he was not Jack Kennedy.) Yet Boswell during his ARRB interview admitted that 1/3 of the total brain was missing and Humes during his JAMA interview (1992, p. 2798) maintained that 2/3 of the right cerebrum was gone; this is also a huge percentage of the total. Although they both unabashedly insisted that they saw no inconsistency with the recorded brain weight of 1500 grams, they offered no rational explanation either. This is not the behavior of reasonable men, yet their entire careers bear clear testimony to their otherwise rational, and widely respected, professional behavior. It is only here in the JFK case that they seem to have lost their way.

The unexplained, even (apparently) egregious, omission of the fresh brain weight is beyond comprehension. Neither of them had any explanation for this. But Boswell's comments to Lifton (cited above) provide the answer. Almost certainly they had measured it, but the results (perhaps on Humes's lost notes and diagrams) had disappeared. Whether Humes immediately knew that this recorded brain weight had to be lost, or whether he only recognized it later, cannot be known, but ultimately it does not matter. The fact is that Humes's notes and diagrams did disappear, meaning that the fresh brain weight could never be used as an indisputable proof that a different brain had later been examined. If the real brain was buried with the body (on Monday, 25 November) as Humes claimed was planned in advance, he may have been aware of this possible snafu well before he submitted his final draft on Sunday, 24 November, and therefore might already have destroyed his notes and diagrams. His admissions to the ARRB seem consistent with exactly this behavior.

The entry wound in the right forehead is yet another issue. Given the trail of bullet debris on the X-rays, and an entry wound in the forehead (seen by O'Donnell in a photograph, and by others on the body), is it possible that the pathologists really did not know? Boswell's unexpected recall (35 years later) of the notch in the right forehead bone speaks volumes. Furthermore, Tom Robinson's unprompted recall of placing wax into just such a hole only increases the probability of the pathologists' feigned ignorance of this site. Even Kamei, who was only occasionally present at the autopsy, recalled this reconstruction work in the right forehead by Robinson, so how could the three principal pathologists have missed it?

Regarding their professed ignorance of the projectile wound to the throat, they stand on dangerously thin ice. Even Ebersole (in his conversation with me) recalled a telephone conversation with Dallas, from which they learned of this wound before the autopsy was over. Ebersole even recalled that certain logical consequences followed from this bit of intelligence: he stopped taking X-rays, because now the mystery (of the exit for the back wound) was solved. Kathy Cunningham's meticulous accounting of the many in the morgue who did know of this wound provides essentially irrefutable proof that the pathologists really did know. Moreover, Robert Livingston, M.D., then the Scientific Director of two NIH institutes (across the street from the Bethesda National Naval Medical Center) and who had extensive experience with gunshot wounds while serving in the Pacific [23](#), clearly described the throat wound directly to Humes by telephone just before the autopsy. Livingston had heard about the throat wound but was naturally puzzled because Oswald had supposedly fired from the rear. He therefore emphasized to Humes the importance of a careful dissection of the neck. [Editor's note: See Assassination Science 1998, pp. 161-163.] Livingston later recounted this episode under oath during Crenshaw's defamation suit against JAMA.

The pathologists' biopsies of the tracheotomy edges and the passing of probes through a supposedly simple tracheotomy make no sense at all, unless they either knew, or at least suspected, that a projectile had passed through the throat. Finally, and remarkably, during his ARRB testimony, Boswell himself shamelessly admitted that he knew of the projectile wound in the throat while still at the autopsy, thus agreeing with one other autopsy physician, John Ebersole. In fact, only three years after the assassination, Boswell had told The Baltimore Sun (Richard H. Levine, 25 November 1966, front page article) that, before the autopsy began, the pathologists had been apprised of JFK's wounds and what had been done to him at Parkland. In particular, Boswell said: " We concluded that night that the bullet had, in fact, entered the back of the neck, traversed the neck and exited anteriorly." Yet, even after all of this, it must be emphasized that an entry wound to the throat is completely absent from the official report. There can be only one intelligible explanation: they understood all too well that such a small, smooth wound to the throat, honestly described, would immediately be recognized as an entrance wound. Furthermore, they also understood that, after all of their probing (especially through the tracheotomy), if this wound were connected to the back wound, it could not be reconciled with a shot from the so-called sniper's nest. [24](#)

In his refusal to discuss JFK's adrenals, Humes had already displayed his willingness to conceal information, even after it had become almost common knowledge that JFK had Addison's disease. Even in front of his own forensic colleagues on the HSCA Forensic Pathology Panel, he refused all comment. [25](#) But we have learned more about Humes from the episode of the burned documents. We now know that he was quite willing to leave or even to create a misleading impression if it served his purpose. The preposterous story of the bloody, burned autopsy notes (which disguised the additional burning of the first draft) proves that he was willing to put out cover stories for his own actions.

If Humes and Boswell participated in the charade of a two-brain examination, in the process duping their associate Pierre Finck, they have indeed opened themselves to the most serious of charges. (It is an astonishing irony that another associate, the

radiologist Ebersole, in turn probably duped them-by altering the X-rays.) By doing so, they not only covered up the most critical evidence, but they also abused the trust of an associate. The evidence that this dishonorable behavior occurred is, unfortunately, very powerful.

As Stringer so clearly stated, when ordered by Captain Stover (of Bethesda) to sign the Naval medical affirmation of 1 November 1966, he signed it-even though he knew it to be false. Can there be any doubt that the physicians, too, were placed under similar pressures to comply? Even Finck, in his testimony at the Garrison trial, admitted, under oath, that Humes was following orders during the autopsy and that he was not autonomous. Humes himself, on other occasions, clearly submitted to the wishes of Admiral Burkley. Humes granted his request for the prompt return of the brain, so that it could (presumably) be buried with the body, and Humes, by his own description, delivered all of the biological materials to Burkley.

In his ARRB deposition, Humes even suggested that he was writing the autopsy report for Burkley. Furthermore, Burkley's rank of Admiral placed him near the top of the military hierarchy, probably second (in this situation) only to the Surgeon General of the Navy, Admiral Edward Kenney, who was also at the autopsy. Humes's background in the military, and also his commitment to the Church, had provided ideal training for his role as obedient disciple. From the very outset, he must have seen the lay of the green. (Humes used a golfing metaphor to close his own testimony.) The pathologists had been told, before the autopsy began, that the sole suspect was already in custody, that he had fired from the rear, and that their job as pathologists was simple, they just had to find the bullet. 26

Even Finck, in more private moments, has expressed his own indignation at the entire affair. The overheard conversation at the AFIP cafeteria (see Aguilar's essay), which was recalled for the ARRB by biochemist Leonard Saslaw, is quite telling. Finck bitterly complained about the immediate disappearance of his autopsy notes, which he apparently never recovered, while he was still in the morgue. Cyril Wecht, M.D., J.D., personally encountered Finck at breakfast in February 1965, at the Drake Hotel in Chicago during their specialty meetings. Although he disclosed nothing specific, Finck was still ruminating about the autopsy, implying that he wished he could recount what had really happened, with the clear insinuation that the most extraordinary events had occurred.

On 29-31 January 1968, a Special Forces captain, John McCarthy, was convicted of murder in South Vietnam, in a case in which Pierre Finck participated in a cover-up (17 August 1995 interview with McCarthy by Jim DiEugenio). Finck controlled a file that contained exculpatory evidence, but whose existence he denied. In March 1970, just after McCarthy had been released from Leavenworth on military "bail," his attorney, Steward Davis, was having coffee in a Pentagon cafeteria, when a lawyer from the forensic pathology department approached him. This lawyer then escorted Davis to Finck's office, where he was shown the "nonexistent" file. He was told that a copy machine was just down the hall, and Davis was left alone. Inside the file was the recantation (of August 1968) of Captain Richard Mason, the expert witness who had testified against McCarthy (and who had remained in the courtroom after his testimony!).

Also included were letters from Finck (who was Mason's superior) to 'Mason suggesting that he get on board (with the .38 theory), and another letter, congratulating him on his recantation. The FBI file of 9 February 1968, with exculpatory evidence, was also present. Davis was therefore certain that both the FBI and Finck knew that exculpatory evidence existed and that nothing had been done about it. DiEugenio implies that the Pentagon was eager to convict a Special Forces man because they (the Pentagon) were not in charge of Special Forces operations. (McCarthy recalls outright glee within the Pentagon at the prospect of a court martial for a Special Forces captain in a case of premeditated murder.) My point in presenting this episode is to show that, like Humes (and probably like Boswell), Finck, too, could be persuaded to follow questionable directives from his superiors.

When Paul Hoch, interviewed Humes immediately after an appearance before the HSCA, he stated:

I wish they'd asked some more questions... I was surprised at the Committee members... They sort of had a golden opportunity, you know. I was there, but they didn't choose to, and it didn't bother me one-way, or the other: whatever pleased them pleased me (Lifton 1988, Chapter 24).

Gary Cornwell (the Deputy Chief Counsel for the HSCA), based on his own experiences, has described Humes's acquiescence to demands of authority (Real Answers 1998, pp. 71-74). Cornwell had decided (and apparently still believes) that Humes had not intentionally misreported the autopsy, but that he was merely incompetent. Based on this, he planned to confront Humes with the lateral X-ray evidence that shows the bullet trail lying nearer to the top of the skull than to the bottom. Cornwell understood well enough that, on national television, he could administer the coup de grace to Humes, so that Humes would have no choice but to admit his (supposed) faux pas in placing the entry wound far too low.

Cornwell, celebrating his unassailable strategy in advance, tipped his hand to a member of the Forensic Pathology Panel. This specialist, readily understanding the power of Cornwell's argument and its inevitable success, tried to dissuade him, on the basis that Humes was a respectable professional who should not be so manhandled. There the matter was dropped, but the next day, just before the session was to open, this same pathologist, acting now as a messenger from Humes, reported that Humes was now willing to confess to error in his autopsy report! Cornwell therefore met privately with Humes and confirmed that this was indeed true. As I observed on videotape (supplied by Wallace Milam) Humes thereupon did exactly that: he pointed to the much higher site on the lateral X-ray as the entry, thus nullifying his own autopsy report and also the entry site that he had previously drawn on a skull for the HSCA. Cornwell concludes by commending Humes for admitting his past mistakes. But then later Cornwell offers his own confession (pp. 188-189):

But I admit that I have not closely followed, much less been actively involved in, all of the continuing research and evaluation of "newly discovered" evidence...

Even though Cornwell's book was published in 1998 (the same year that the ARRB concluded its work) there is no mention of the ARRB's existence, or of its over 60,000 newly released documents. Nor is there any mention of the JAMA articles (of 1992) in

which Humes totally ignores his HSCA testimony (the one that had so pleased Cornwell) and in which he once again reverts to the low entry site! But my point is mainly about Humes, not about Cornwell. Humes was quite agreeable to changing his testimony under pressure even though his conversion was obviously not authentic, nor was it long lasting. How likely is it then, that when under even greater pressure (such as at the autopsy), Humes would somehow have resisted such pressure and stoutly reported only the facts, without a trace of deviousness?

Unquestionably, the pathologists were under enormous pressure, the kind that most ordinary individuals never encounter. Their careers could well have been permanently jeopardized. From the comfort of a recliner nearly forty years later, it is all too easy to judge them by our own standards. They had been driven into an impossible cul-de-sac, whether to obey their own internal ethics, morality, and honesty (and to let the facts fall where they may) or to conform to the rigid, authoritarian structure that had nurtured and protected them for so many years. But this same structure now would tolerate only one answer: the lone assassin. We can only dream of the conflicts that seethed in their own conscious (and subconscious) minds, nor can we know with certainty how they resolved these issues for themselves as the years passed.

Like most of us, however, it is probable that, once a decision had been reached, second thoughts were few. Most likely, these became increasingly fewer as the years passed. Furthermore, as psychologists know so well, when something is believed for long enough, it begins to take on the texture of truth. So it is even possible, after a while, that the pathologists began to believe that only two shots had been fired from the rear. As memory experts know from countless experiences, the human mind is incredibly flexible, quite capable of adding hues and textures, not originally present, to the silver screens of human memory, especially as time overtakes us all.

Nevertheless, I still have some doubts about this scenario. Why, for example, did the pathologists take so long to agree to be interviewed by JAMA by a fellow pathologist (George Lundberg, M.D.) no less, a former military man, and a friend of one of them (Humes)? Why did they dodge the press conference that Lundberg had to manage by himself in front of the AMA logo? Why did they simply not volunteer to come to the ARRB rather than actually requiring the delivery (for Humes and Boswell) of a subpoena for their final bow? Let me be quite honest. I suspect that they had not totally forgotten, that they really did recall some of the things they had done, and that such memories were still too sensitive to be publicly exposed. But perhaps I am wrong. About such things we can only speculate. But I still wonder.

Whenever possible, the pathologists told the truth, as they did regarding the EOP entry site. For this fact, their innate adamancy and professionalism rose to the fore. Their refusal to accept the red spot as an entry wound, their refusal to recognize the 6.5 mm object as present on the original frontal X-ray, and their insistence that they had taken photographs no longer in evidence, all of these attest to their honesty and competence.

But there is another side, too. Boswell agreed to elevate the back wound to comply with the SBT; Humes moved the metallic debris downward by over 10 cm (and ignored this obvious evidence for a second headshot); neither of them were willing to impeach the

photographs of the back of the head (showing an impossibly intact scalp); Humes burned his first draft (or drafts) and put out a ridiculous cover story; Humes refused to be forthright with respect to the adrenals; all of them pretended, at least for a while, that the throat wound was invisible at the autopsy; all ignored the evidence for a frontal headshot; Humes successively changed his opinion about the SBT (finally accepting it); he successively changed the width of the tracheotomy; and Humes (alone) even once agreed that the posterior entry wound lay high on the skull.

When the pathologists behaved irregularly, it was not out of malice or of caprice nor usually from incompetence, but because they had been boxed into a corner, where they really had little choice, either because of external constraints placed upon them, or because of internal constraints due to decisions they themselves had already made about the facts of the case. Having walked so far down this road, it was unlikely that they could ever, even to themselves, admit, or perhaps even recall, had they wished, the path that had carried them to their final destination. Their responses before the ARRB, as shown so clearly in the excerpts presented in the addenda, are more than sufficient proof of the state of their minds. It is unlikely that a frank confession of their misdeeds, as some of their critics would have desired, would ever have been forthcoming. We must instead be content with our present knowledge of what actually transpired during those critical hours and days, knowledge that is much fuller today than it was even five years ago.

Indeed, several other odd events are consistent with the above interpretation. During the Garrison trial, when Finck seemed to be saying a bit too much (as Boswell actually stated in his own ARRB deposition), Boswell was rushed to New Orleans to back Finck up as needed (or perhaps even to contradict him), but he was never called to the stand. It is certainly intriguing that Boswell was invited to supervise the autopsy of Martin Luther King (recounted in Boswell's ARRB deposition), an invitation he declined. Humes's involvement in LBJ's benign biopsy is also curious; some cynics have wondered if Humes's involvement was a reward for his work in the JFK matter.

A final comment seems appropriate. These Bethesda doctors are not the only physicians to adjust their sails to the political winds. The physicians at Parkland are hardly blameless, either. Recall that, although they initially agreed that shots had been fired from the front, when they testified before the Warren Commission, their stories changed. In fact, as Crenshaw reports (Palamara 1998, p. 31), following the visit of the Secret Service, which included a briefing about the official autopsy results, almost all talk among the physicians about the autopsy came to a halt. Most notably, Malcolm Perry, who had thrice described the throat wound as an entry wound during his press conference, later did a complete about face, now agreeing (despite seeing no objective new evidence) that it was an exit wound, after all. (Regarding Perry's quite different private comments, see the "Afterward" in Lifton (1988).)

So powerful was the social pressure over this issue, that several of the Parkland doctors, who had so clearly described cerebellum as extruding from the head wound (these summaries are actually in The Warren Report, many in the doctors' own handwriting), later changed their story and said that the cerebellum was now safely back inside the skull, even though, in the interim, they had seen no new physical evidence. When JAMA published its pathetic attempt to whitewash the government's

account, his former colleagues convicted Crenshaw of publicity seeking, even though they agreed with Crenshaw about the wounds. 27 Crenshaw's colleagues had merely raised their fingers into the political breezes; to see which way the winds were blowing. They clearly did not wish to tack into any stormy seas.

That the physicians at both Bethesda and Parkland succumbed to authority should not have surprised us. As Robert Proctor recounted ("Racial Hygiene: The Collaboration of Medicine in Nazism," in *Medicine, Ethics and the Third Reich*, ed. John J. Michalczyk, 1994, p. 36), 3000 doctors (6% of the profession) joined the National Socialist Physicians' League by January 1933, before Hitler rose to power! Proctor states: "In fact, doctors joined the Nazi party earlier and in greater numbers than any other professional group. By 1942, more than 38,000 doctors had joined the Nazi party, representing about half of all doctors in the country."

F.A. Hayek (*The Road to Serfdom* 1944, reprinted 1994, p. 209) also comments on this all too predictable behavior: "The way in which... with few exceptions, her [Germany's] scholars and scientists put themselves readily at the service of the new rulers is one of the most depressing and shameful spectacles in the whole history of the rise of National Socialism. It is well known that particularly the scientists and engineers, who had so loudly proclaimed to be the leaders on the march to a new and better world, submitted more readily than almost any other class to the new tyranny." Hayek also cites R. A. Brady (*The Spirit and Structure of German Fascism*) as concluding that the scientist is perhaps the most easily used and "coordinated" of all specialists in modern society.

Was G. Robert Blakey aware of these behavior patterns when he took control of the HSCA and promptly (and intensively) began to employ precisely these specialists?

A Summary of the Medical Evidence

1. Two headshots were fired, the first striking JFK low on the right rear, in agreement with the pathologists; the second struck later from the front, at the hairline, just above the outer border of the right eye socket. To be consistent with the metallic trail on the lateral skull X-ray, this must have occurred when JFK's head was erect, such as in Zapruder frame 321. This latter shot did not originate from the grassy knoll, but may have been fired from the storm drain on the north overpass, where so many bystanders gathered immediately afterwards.
2. The trail of metallic debris on the X-rays is consistent with this second headshot.
3. The 6.5 mm "metallic" object was later added to the frontal X-ray. Actually, a fresh X-ray film was double exposed in the darkroom, first with the image of the original X-ray and then with the 6.5 mm object. This resulted in an undetectably altered, new frontal X-ray. The original X-ray was then either deliberately lost or destroyed. This curious 6.5 mm object, being identical to the caliber of the Mannlicher-Carcano, was then used to tie Oswald to the crime.
4. A large orange-sized hole was present at the right rear of the skull, consistent with the exit of the frontal bullet.
5. Something struck the back (probably from the first shot fired), but did not penetrate. Besides a bullet, other possible projectiles include shrapnel, or even a piece of the street or sidewalk.

6. A projectile entered the throat, but did not exit. The nature of this projectile is still debated, with some (e.g., Lifton) arguing that it was a bullet that was (illegally) extracted before the autopsy, while I have here proposed a second possible projectile, namely, a glass fragment from the windshield. The available evidence does not permit a final choice. That the tracheotomy wound was enlarged, during a surreptitious search for such a projectile, is likely. Evidence also suggests that the head wounds were altered, probably in a search for bullets or bullet fragments.
7. Critical photographs were removed from the original autopsy collection, mostly those of the large posterior hole. Although it is not essential to an overall view of this case, I have concluded that photographs were altered, mostly to hide the large exit wound at the rear. In addition, the body itself (and at least one photograph seen by Joe O'Donnell) did show a right forehead/temple bullet entry. All of this evidence, if it ever existed, has long since been deeply buried, with the exception of the X-rays, which still contain surprising evidence for precisely such a frontal shot.
8. A second brain was substituted for the genuine brain. At the time of the official brain exam (of this different brain), the real brain may already have been buried with the body, although its actual whereabouts cannot be known with certainty (except perhaps by the Kennedy family).
9. The pathologists told the truth, insofar as they could, so long as it did not damage the lone assassin theory. What they themselves actually believed probably lies beyond our knowledge, but this no longer matters. When they could not tell the truth without traumatizing the lone assassin theory, they sometimes had no choice but to lie and to cover-up. I have tried, not always successfully, to sympathize with their almost unimaginable plight.
10. High government officials had to approve, and probably to transmit, orders for alteration of critical forensic evidence, e.g., photographs, X-rays, and the physical evidence. The Secret Service, led by James J. Rowley, held the critical autopsy materials. Possibly a small number of critically placed individuals tacitly understood what needed to be done, and few words were ever actually exchanged. Persons who might have warranted a grand jury investigation were:
 - a. Robert Knudsen, White House photographer;
 - b. James J. Rowley, Chief of the Secret Service;
 - c. Admiral (Dr.) George Burkley.

It is interesting that all three


- a. Worked out of the White House
 - b. Retained their jobs during the LBJ administration (in which loyalty mattered)
 - c. Like LBJ, believed in a JFK conspiracy.
11. The effort to manipulate the physical evidence could easily constitute an entirely separate essay. The actual appearance of the largest metal fragment removed from the skull (still housed at the Archives, where I have examined it) compared to

its supposed identical, but obviously different, appearance on the skull X-rays is merely one issue.

12. All of the official government inquiries were hamstrung by the manipulated medical evidence, by the misrepresentations of the pathologists, and by these agencies' own surprising, and (apparently) naive, lack of suspicion. Given the state of the medical evidence, the (apparently) sincere testimony of many experts, was not necessarily wrong, it was merely irrelevant.
13. The efforts of political bodies of inquiry that are beholden to others (e.g., the Challenger disaster, see Richard P. Feynman, *What Do You Care What Other People Think?* (1988), not discussed here, is a remarkable example of this class) are inevitably emasculated by often, conflicting lines of loyalty. The exertions of the ARRB, which was not really an inquiry at all, but only an information gathering adventure, was, in many respects, a superior model for future panels. This board was beholden to no other entity (or individual). Although criticisms have inevitably been leveled at it, both by some of its staff and by those of us who mostly just observed, it is likely that its private citizens merely tried to do their best. It may be difficult to do better than that. It is possible, however, that future inquiries could build on this model. Perhaps the process should be divided into two stages:
 - a. The collecting of all possibly relevant evidence (modeled after the ARRB)
 - b. A subsequent panel totally unrelated to the first that actually makes decisions based upon all of the evidence (perhaps even employing a jury of ordinary citizens, when that is appropriate).

This suggestion is somewhat analogous to grand jury proceedings (at the first level), and the subsequent actual trial (at the second level), although for grand juries the same individuals may be involved at both levels.

Postscript: The Mystery Photograph F8



The mysterious skull photograph alongside Mantik's analysis of photograph F8

Autopsy photograph F8 (the label derives from the list of Fox photographs) has generated endless controversy. This view has been exceptionally difficult to orient, even for the pathologists. Line BA was interpreted by Michael Baden, M.D., of the HSCA as passing from left to right, with the visible bone lying immediately anterior to the coronal suture. In fact, point B lies deep in the occiput, while point A is situated toward the front of the skull. Line BA divides the skull into left and right. Point L identifies the lead deposit on the Harper fragment; its location on the skull is remarkably consistent with the pathologists' skull entry site. The small white triangle identifies a triangle discussed in the text. The black circumferential perimeter outlines the site of origin of the Harper fragment. Letters C and D identify small bone fragments that are also identified in Figures 4A and 7. In F8 the Harper fragment appears distorted because of the perspective offered by the camera. Beyond point A (in the photographs at the Archives) a tangential view of the chest and abdomen (with fat pads folded back) can be seen. I determined this by stereo viewing of two, nearly identical, color photographs of F8.

In this section I present proof that this photograph (B& W # 17, # 18 and color #44, #45 in the current collection) shows the posterior skull. Even Robert McClelland, M.D., insisted, after his visit to the Archives, that the collection included a view of the large hole as seen at Parkland Hospital. It must have been F8. During their initial inventory review (signed on 10 November 1966), the pathologists labeled this as a posterior view: "Missile Wound of Entrance in Posterior Skull, Following Reflection of Scalp." Furthermore, in his ARRB deposition (reported to me by Douglas Home), Humes located the entry wound (in the posterior skull) toward the bottom of this photograph (as oriented here). This agrees with my interpretation, but disagrees with Baden, who described it more as a view from the left side. At their ARRB depositions, none of the pathologists could orient this photograph. However, when the X-rays are used in conjunction with the photograph, then its orientation becomes unambiguous, as I describe here in stepwise fashion.

1. Note the remaining frontal bone (Figure 12), as determined from the frontal skull X-ray. This is consistent with Boswell's drawing at the autopsy (Figure 4A) and also with his drawing for the ARRB, as rendered by Home (Figure 9A-D). Note that the upper edge of the remaining frontal bone lies close to the hairline. Although not shown here, these drawings are also consistent with the drawings of Angel, the physical anthropologist, who served as an expert witness for the HSCA (7HSCA228-230). Giesecke (6H74) is one Parkland physician who did describe the large skull defect as extending from the occiput to the browline, in remarkable agreement with Boswell.
2. On the lateral skull X-ray (Figure 11B), I have indicated, with a line passing through the metallic debris, how the X-ray beam would have transited the skull when the frontal X-ray was taken. For confirmation of this X-ray trajectory note that (a) on the frontal X-ray (Figure 14) the metallic debris is closely bunched from top to bottom, as would be expected if the X-ray beam were traveling nearly parallel to this debris, (b) the transverse fracture just above the left eye (on the right side of the page) corresponds to the discontinuity at the rear of the lateral X-ray, and (c) the 7 x 2 mm metal fragment lies well above the right eye socket on both views. (There is additional evidence for this conclusion not given here.)

3. On the frontal X-ray, all of the bone is absent just above the trail of metallic debris.
4. In the HSCA interpretation of F8 (I have watched Baden demonstrate this on television), the segment BA runs from left to right across the skull at the coronal suture; therefore, according to the photograph, almost all of the bone anterior to this line segment was intact. This conclusion made some sense, because the largest, late arriving bone fragment had a suture line at one edge, which the HSCA took to be the coronal suture. Angel agreed that this was the coronal suture, but he placed this bone fragment anterior to the coronal suture, whereas Baden (in an unintended confirmation of the confusion that reigned over this issue) placed it posterior to the coronal suture. [What convinced Baden was the semicircular notch just below the letter C in the photograph) at the edge of the bone, which he took to be the exit site for the posterior bullet. Furthermore, this largest, late arriving bone fragment showed (on its X-ray image) multiple, tiny, metal particles, strongly suggestive of an exit site, meaning that it had to fit next to the notch (in Baden's view). The largest bone fragment can probably be placed anterior to the coronal suture (as Angel did), thus still permitting the actual exit site to lie at or near the coronal suture. (The X-ray's leave an irresolvable ambiguity about the orientation of the bone fragments: it is impossible to distinguish inside from outside, and, strangely enough, the pathologists said nothing to clarify this. No photographs were taken either.)
5. Notice, however, that we have now arrived at a *reductio ad absurdum* there is a fatal contradiction in Baden's interpretation: from the X-ray s, we know that bone must be missing all the way forward to the hairline, but Baden has just told us that it is present all the way back to the coronal suture! (On the lateral X-ray, this is where the skull is fractured at the skull vertex.) If the bone really were present to the coronal suture, then, on the frontal X-ray, we would see bone right at the very top on the right side of the skull, just as it is present on the left side. We can be certain of this because we know (from step 1) what the beam's eye view is, i.e., we know the direction that the X-ray beam traveled at the top of the skull during the taking of the frontal X- ray. Therefore, Baden's orientation of F8 is certainly wrong.
6. On the other hand, if F8 is the back of the head, then the line segment BA is the midsagittal line. There is further confirmation that this is the correct. While at the Archives, I viewed this photograph and its near twin (most views are pairs, taken with the camera slightly displaced in successive views) with a stereo viewer, which, for this view, is particularly illuminating. The bone surface (left of midline) was quite rounded, as would be expected for the occiput. In addition, the fractured bone islands at the right front (labeled C and D) could now be appreciated in 3D. After some staring, I realized that there were only two, and that they corresponded to the two bone islands on the frontal X-ray (also labeled C and D). Their sizes, shapes, and locations all fit perfectly. But one additional feature surprised me. In the color photographs at the Archives, there was more to see beyond the top edge of the film than is visible here. I finally realized that I was looking tangentially across the chest and abdomen. I could actually see a nipple (extending out into space in 3D) and the biggest surprise; I could see fat pads folded back from the abdominal incision.

7. There is a specimen bottle at the bottom left of this photograph (not well seen here), which seemed to suggest that Baden might have been right after all. However, now that I knew where parts of the body were located, I could conclude that the head had merely been rotated into a nonstandard orientation, no doubt to better expose the large, occipital hole for the camera, and that the specimen jar posed no special problem in interpretation.
8. Having concluded that the large defect extended all the way to the anterior hairline, Boswell's 13 cm measurement for the large hole fits better than it would for an anterior border at the coronal suture. This is further confirmation of my conclusion.
9. When questioned about this notch (on the bone edge) in F8 by the HSCA, Humes (7HSCA249) did not hesitate to say that the notch was not in the frontal bone, thus disagreeing with Baden's orientation!
10. In conclusion, the orientation described here is consistent with the historical orientation, with the X-rays, with Humes's comment about the notch, with Boswell's two drawings (one at the autopsy and one for the ARRB), and even with Angel's drawings, but not with Baden's orientation. From this photograph, we can be certain that the back of the head was blown out, quite dramatically in fact, just like all of the witnesses said. It is very difficult to escape the conclusion that a frontal headshot led to this injury. This deduction, of course, also corroborates the recollections of all of those new and old witnesses who saw autopsy photographs with such a massive defect, which, in turn, means that other photographs really have disappeared.

Acknowledgments

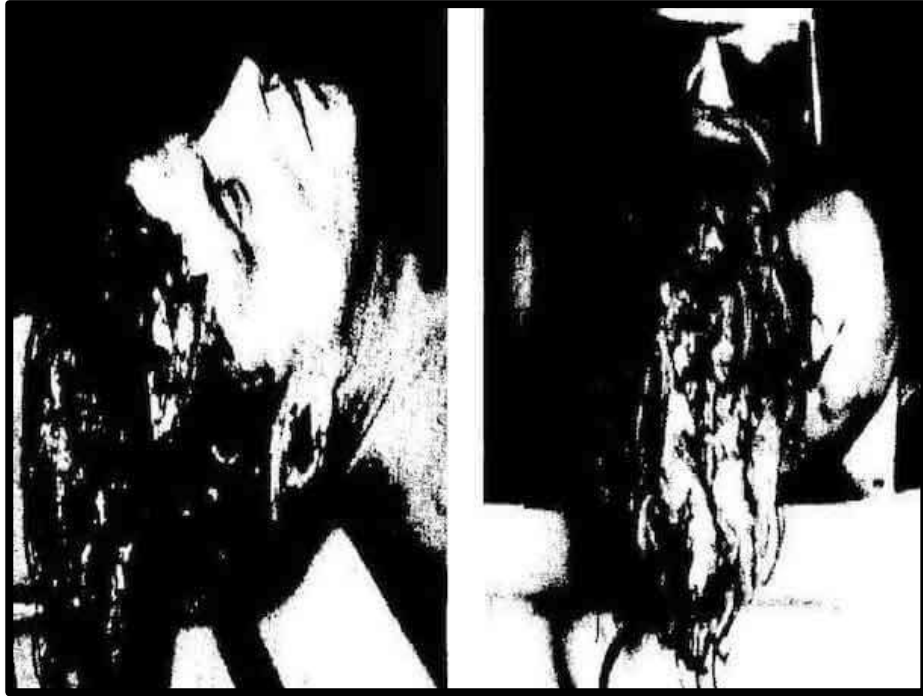
Harry Livingstone and David Lifton are justifiably recognized as primary trailblazers in the medical evidence. Their books served as invaluable guides during the period of my initiation. I later had the pleasure of meeting and collaborating with both. By responding promptly to my initial letter of inquiry, Cyril Wecht, M.D., J.D., greatly encouraged my initial ideas; he has continued to be a bastion of support. An unintended consequence of JAMA's sorry attempt at journalism was my introduction to Gary Aguilar, M.D. and to James Fetzer. I owe much to both. My seemingly inevitable and uncanny agreement with Wallace Milam, on almost every issue, was a source of great encouragement. Kathy Cunningham often served as an inexhaustible resource, not just for me, but also for many others. I am also indebted to Roy Schaffer and Millicent Cranor for sharing their insights with me. These, and many others beside, have made my own work possible. For their contributions to the cause of truth, I hold them all in high regard; they have served their country well.

Notes

1. Spence (for the defense) and Vincent Bugliosi (for the prosecution) opposed one another in the television production, *On Trial: Lee Harvey Oswald* (London Weekend Television) and shown on Showtime (1986).
2. This is based on a personal conversation with Douglas Home (and Patricia L. James, M.D.) at the San Francisco airport on 12 March 2000.
3. Since I had set a deadline of 15 April 2000, I called Tunheim's office on 26 April. I was informed that the questionnaires had indeed been mailed out (on about 20 March 2000) but that no replies had been received. When this book went in press in June, still no responses had been received.
4. The traditional approach is well demonstrated in Cyril Wecht, *Grave Secrets: A Leading Forensic Expert Reveals the Startling Truth About O.J. Simpson, David Koresh, Vincent Foster, and Other Sensational Cases* (1996).
5. Perhaps because I have established that the X-rays have been altered, it is easier for me to surmount the emotional and psychological hurdles that obstruct belief in photographic alteration. There is nothing like personal experience to open one's eyes.
6. David Lifton has advised me that he first saw prints of the autopsy photographs in spring 1981, when he went with Mark Crouch to visit James K. Fox. Lifton obtained prints in December 1982 from Crouch, who had made copies from Fox's set. In that same month, and in January 1983, Lifton became the first person to show actual prints of the autopsy photographs to the Parkland medical personnel. As before, the images surprised them. Lifton has recounted his own experiences in the Afterword to *Best Evidence* (1988, p. 703). Malcolm Perry's surprised reaction to the tracheotomy makes for especially interesting reading.]
7. Groden (1993, pp. 83-84) illustrates the large hole. Although this is fairly accurate, the X-rays show that the large hole extends anteriorly to the hairline. A drawing of the posterior skull by autopsy lab technician, Paul O'Connor, is surprisingly accurate (Groden 1993, p. 87).
8. Blakey and Billings later wrote a conspiracy book in which they implicated the Mafia (G. Robert Blakey and Richard Billings, *Fatal Hour: The Contract, the Killing, and the Cover-up* 1981). Cornwell also authored a conspiracy book (*Real Answers* 1998).
9. Addresses and phone numbers are in my files.
10. Livingstone (*High Treason* 1998, pp. 501-536) reprinted Spencer's complete transcript. Livingstone also summarized the new medical evidence (pp. 403-543), a synopsis that was very useful for my own synthesis.
11. Roger Feinman, a former employee of CBS, graciously supplied this information. This CBS documentary of 25, 26, 27, 28 June 1967, with Walter Cronkite narrating, was critiqued in Josiah Thompson, *Six Seconds in Dallas* (1967).

12. After listening to these interviews on audiotape, I was struck by how often, and with what great emphasis, all three family members stated that their father was highly secretive about anything related to the autopsy. For example, none of them knew for certain where he had gone to testify in 1988, and, although they seemed to understand that he did not accept the Warren Report, he had actually never stated his opinion directly. They clearly understood that he wanted to avoid any public discussion of this entire issue.
13. I am not at all persuaded, based merely on his description, that he saw the original film. What is more likely is that he saw a copy of the original that was distinctly different from any extant copy.
14. Dennis Breo, JAMA (27 May 1992), pp. 2794-2807.
15. Seth Kantor was a friend of Jack Ruby. He recalled seeing Ruby at Parkland Hospital shortly after the shooting, but the Warren Commission chose not to believe him. Kantor later published his own account of these events (Seth Kantor, *Who Was Jack Ruby* 1978), in which he described Ruby's ties to the FBI, the CIA, and to organized crime.
16. Charles Crenshaw, *Conspiracy of Silence* (1992); also see *Assassination Science* (1998), pp. 37-60.
17. It is probable that Stewart, like so many others in this case (including Robert Blakey, on a national talk show), has reversed left for right. Although this cannot now be known with certainty, Crenshaw's recollection of a right frontal entry wound would seem consistent with this interpretation. That Stewart, after discussing this issue with the other Parkland doctors, would still speak out publicly, sometime later, on this matter is surely a demonstration, at the very least, of his true convictions.
18. For a detailed chronology of the tracheal wound and its varying descriptions over the years, see Lifton (1988, chapter 11). Lifton also notes that Baxter, at Parkland, placed the incision at the second ring (6H42), while the autopsy report placed it at the third and fourth rings.
19. His closest boyhood friend was Henry Zapruder, son of Abraham Zapruder.
20. See Vincent DiMaio, *Gunshot Wounds* (1985), pp. 80-85, and especially J. Thornton, "The Effects of Tempered Glass on Bullet Trajectory," *AFTE Journal* 15 (July 1983), p. 29.
21. For the behaviour of ricochet bullets, see DiMaio (1985), pp. 88-92.
22. See the discussion of the Harper fragment in Palamara 1998, pp. 74- 75
23. Livingston and I have since become good friends, visiting at one another's homes, even taking a trip together, and he has consistently repeated this same story. It is certainly in character for him to have involved himself in such a matter. His prior presidency of Physicians for Social Responsibility (an organization that won a Nobel Peace Prize) speaks volumes about his willingness to take unusual responsibility upon himself.

24. Since the throat wound so obviously arose from a frontal projectile, I had predicted that JAMA would not have the courage to describe the physical characteristics of the throat wound, but that, instead, they would merely employ innuendo to impugn physicians such as Charles Crenshaw for saying that it was an entry wound. Unfortunately, I was right. As a result, JAMA later paid Crenshaw \$213,000 in a legal settlement, a quite avoidable public relations faux pas. Astonishingly enough, the editors of my own journal lacked the courage even to admit their error to a fellow physician, Charles Crenshaw (Assassination Science 1998, pp. 37-60). As an AMA member, I felt that my professional dues had been abused during this disgraceful escapade. I later resigned from the AMA, in protest over its unethical behavior.
25. I discussed Humes's willingness to follow authority and to do so with surprising tenacity (a trait I could not relate to) with a close friend who is a Catholic, a Notre Dame graduate, and a university affiliated psychiatrist. He explained to me that Humes's military background, his training as a Catholic, and his continued activity in the Church (even on Saturday morning, 23 November), provided perfect training for his obedience to authority figures. Gary Cornwell's book offers further insight into this side of Humes; for Cornwell's story, see my analysis of the pathologists' characters.
26. If they were really faced with a 6.5 mm bullet cross section (on the frontal X-ray), obeying their orders should have been simple, they had only to extract this object. That they so obviously failed even to search for this 6.5 mm object is striking.
27. When five Parkland doctors were deposed by the ARRB, Jeremy Gunn made exactly this point, the doctors really did agree about the wounds, after all.



[Editor's note: During the deposition (Appendix G), Gunn asks Humes whether the hair was cleaned before photographs were taken, because some of the alleged autopsy photographs (above) are inconsistent with others of the back of the head. They can't all be authentic, but like most of the evidence in this case, they can all be faked. For those who are familiar with the evidence and are not cognitively impaired, this case bristles with smoking guns. (See Robert Groden, *The Killing of a President* 1993, pp. 82-85.)]